# "How and Why Juries React to Medical Graphics"

October 26th (1-2 PM)
New York Academy of Trial Lawyers

Presenters:
John Romano, Esq
Bob Shepherd, MS, CMI
Laura Jordan, Esq

## Introduction

Opinions regarding what make graphics more or less effective are just like noses – everybody has one. For many years, "opinions" regarding specific characteristics of illustrations have been expressed as "fact" but often with no supporting empirical evidence. This has long been a topic of discussion amongst John Romano, Esq of West Palm Beach; Bob Shepherd, MS, CMI of MediVisuals in Richmond, VA; Doug Beam, Esq of Melborne, FL; and Harvey Moore, PhD of Trial Practices Inc. in Tampa, FL. This diverse group discussed specific characteristics of visuals and how to scientifically evaluate their effectiveness. Over the course of several years, numerous images have been created to evaluate several specific traits or characteristics of visuals. Consistent with the scientific method, the images were identical except for one variable trait or characteristic.

The slower demand for case preparation due to court closures during COVID allowed the study to be finalized. After completion of the graphics and discussion of the specific visual variables as well as the methodology of the study, two leaders in online surveys were contacted: Chris Denove, JD of Trial Survey Group and John Campbell, JD of Empirical Jury, LLC. Chris and John were provided with the general objectives and given freedom to perform the study in ways that would be scientifically and statistically valid as well as non-biased.
The surveys designed by Chris and John along with the images were then sent to several hundred respondents who reviewed the images online and answered specific questions regarding the visuals. Most of the images evaluated in the studies performed by Trial Survey Group and Empirical Jury were the same. Many of the questions asked were very similar. The biggest difference in the two studies was that, in one study, the respondents were shown both images and asked to choose which was stronger with regard to certain sought-after characteristics of a demonstrative aid intended to show damages. In the other study, half of the participants saw only one of the two images, and the other half of the participants saw the other image. Neither of the respondents were aware that another image existed or that the image was being compared to another.

To further minimize any additional factors (aside from the isolated, variable characteristic) that might influence the interpretation of the images, no written or verbal explanations of the images were provided in order to avoid varied interpretations of such language skewing the results of the study.

Some of the questions jurors responded to included:

- *Perceived expense of the graphic* – Because the perceived expense of a graphic can make an insurance adjustor aware that a significant investment is being made in the case and therefore, indicating that the case likely has merit and value. Likewise, jurors are more

likely to think a case involves considerable monetary value if it appears a significant amount of money is being spent on it during trial.

- *Perceived Professionalism* – Because professionalism adds to the perception of overall credibility of the trial team.
- *Perceived "precision"* – Because precision adds to the perception that the graphic is believable, and that believability can carry over to the expert who is testifying and to the plaintiff's entire trial team.
- *Clarity and understandability* – Because graphics in general should make someone's testimony clearer and more understandable.
- *Severity of the injury or surgical procedure depicted in the graphics* – Because it is important for insurance adjustors or jurors to gain an accurate and truthful understanding of the severity of injuries and/or the invasive nature of surgical procedures to fairly place a monetary value on them.
- *Monetary value of the injury* – One of the most important and relevant factors but one that was most difficult to incorporate into the survey.

Some of the characteristics analyzed included:

- Simple vs complex graphics
- "Colorized" MRI vs MRI scans alone
- Illustrations of MRI scans vs "colorized" scans
- Amateurish graphics vs professionally developed graphics
- Cross-sections vs no cross-sections
- Realistic and truthful vs diagrammatic

On the following pages are several of the images included in the comparison and the results.

## Results

### Fractured Femur


**X-Ray Only**


**Realistic Illustration**

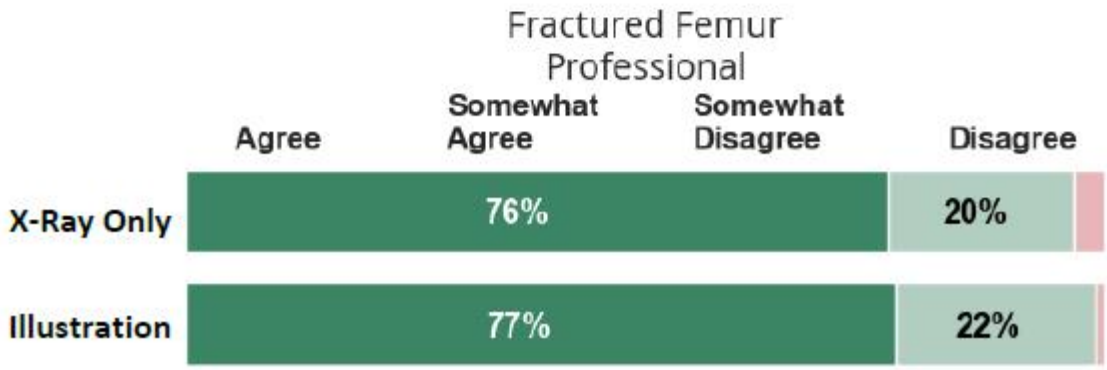


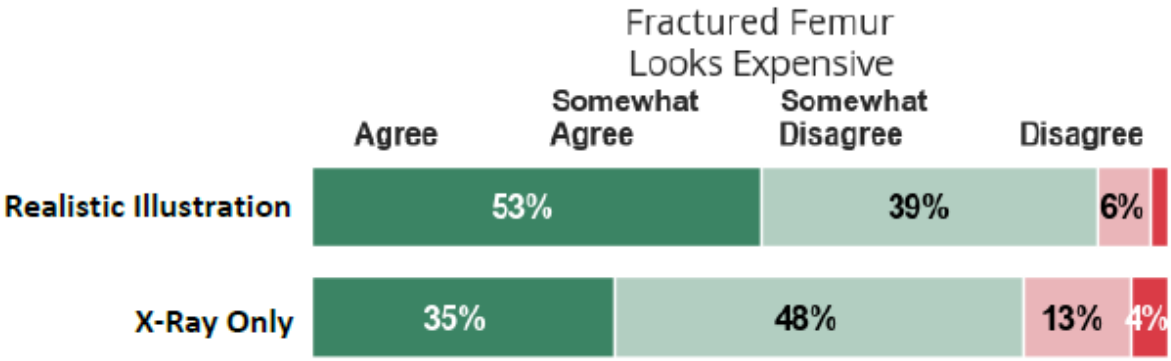

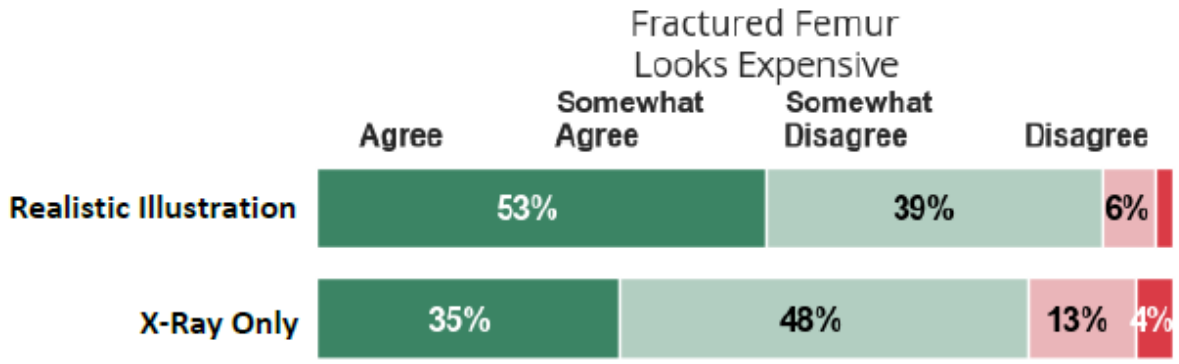
Fractured Femur
Looks Expensive
Agree
Somewhat Agree
Somewhat Disagree
Disagree
Realistic Illustration
53%
39%
6%
X-Ray Only
35%
48%
13%
4%

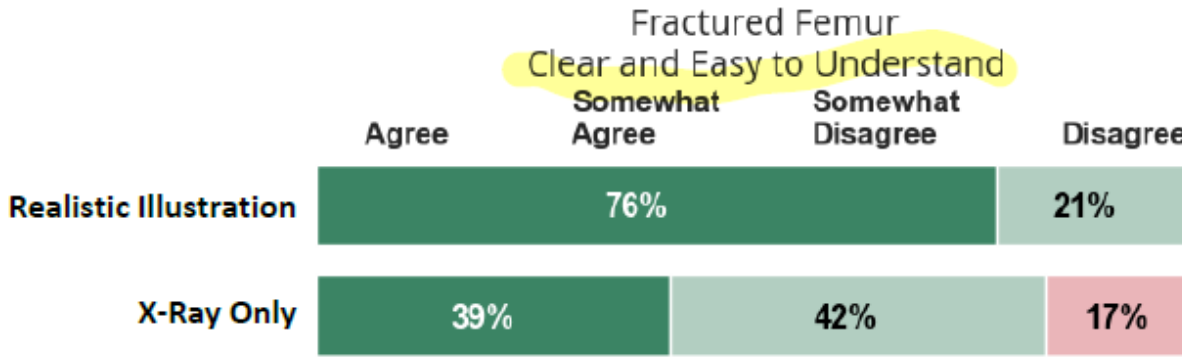
Fractured Femur
Clear and Easy to Understand
Agree
Somewhat Agree
Somewhat Disagree
Disagree
Realistic Illustration
76%
21%
X-Ray Only
39%
42%
17%

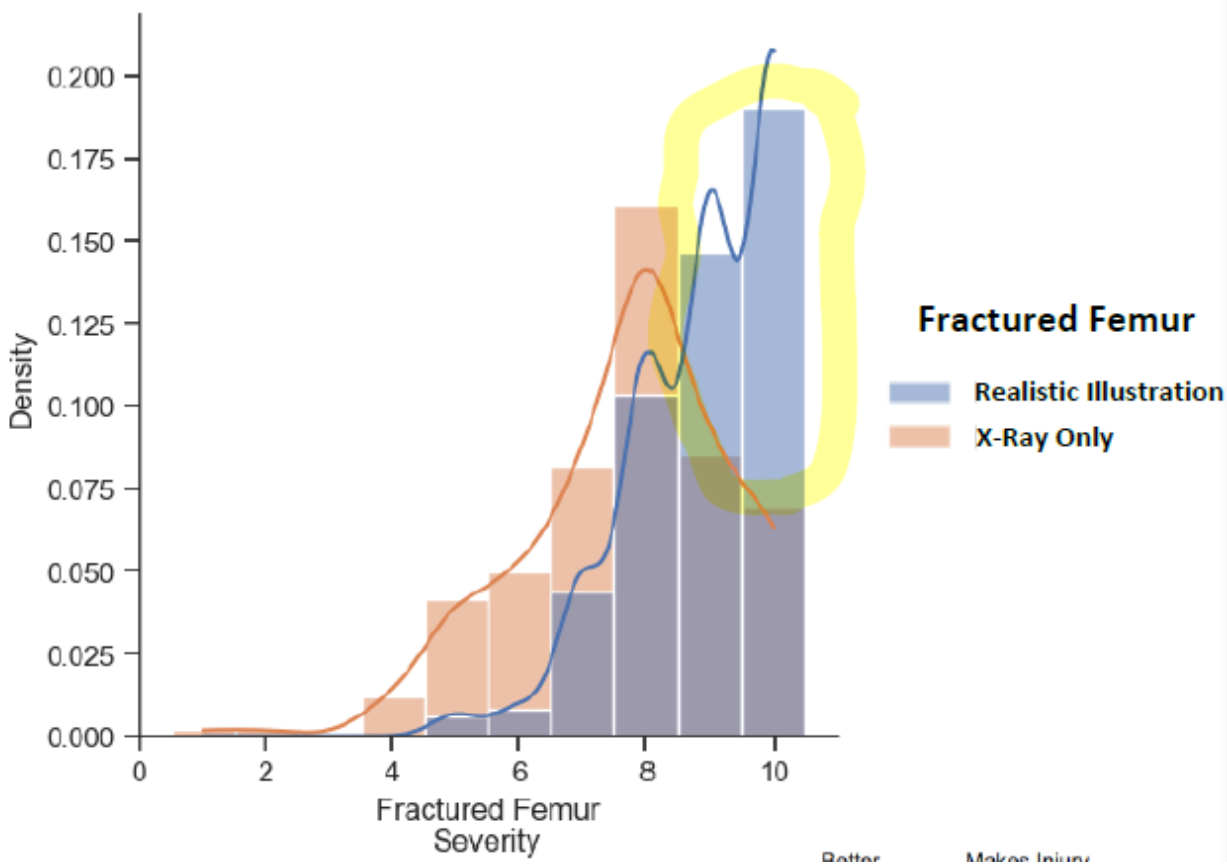
Density
0.200
0.175
0.150
0.125
0.100
0.075
0.050
0.025
0.000
0
2
4
6
8
10
Fractured Femur Severity
Fractured Femur
Realistic Illustration
X-Ray Only

# ORIF of Fibula Fracture

## Bones & Hardware Alone

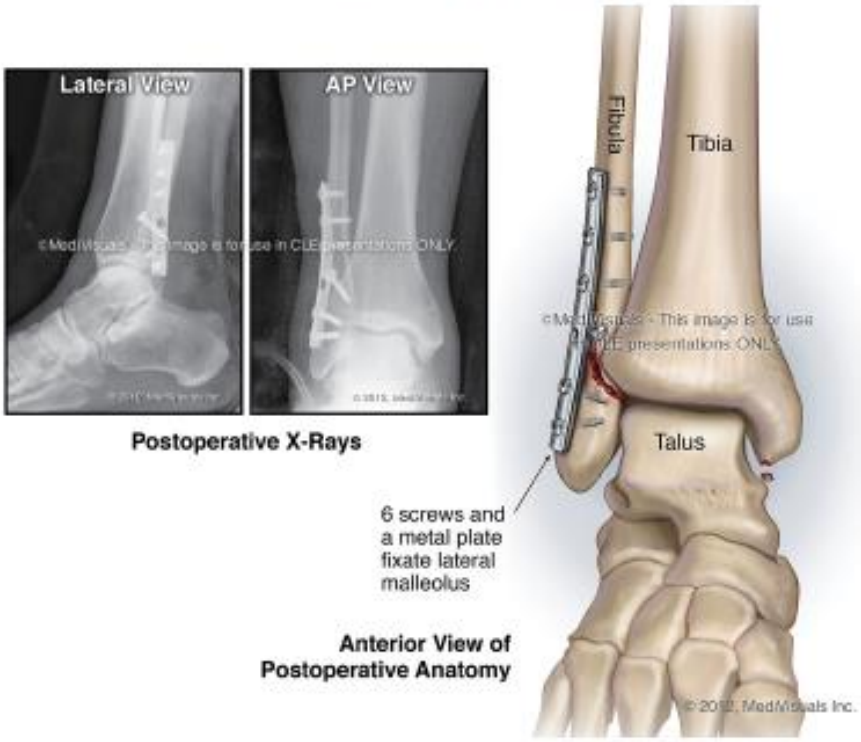


## With Intra-op Trauma Image

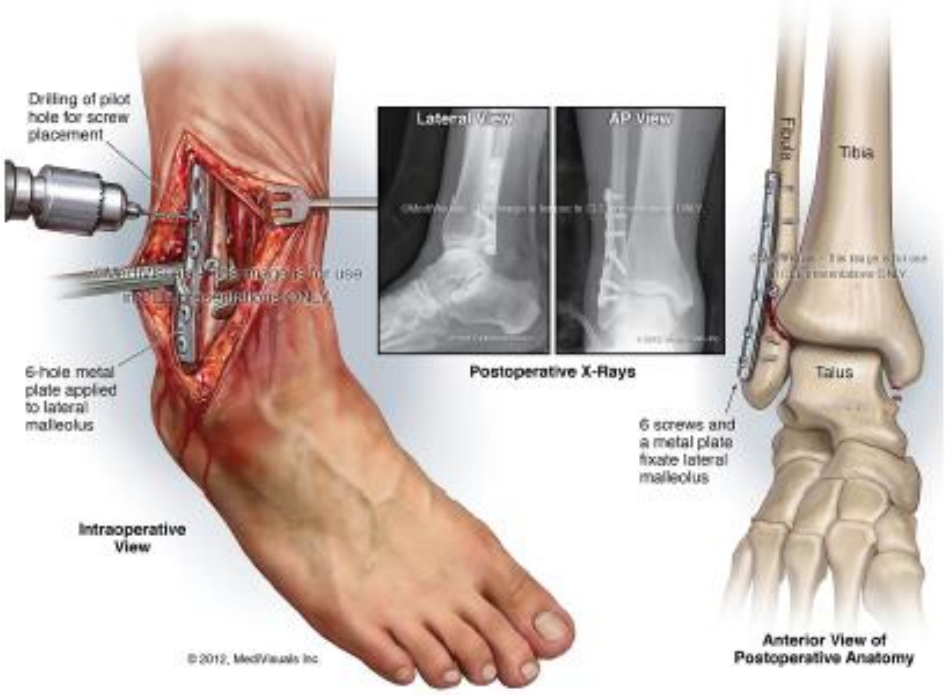

# ORIF of Fibula Fracture

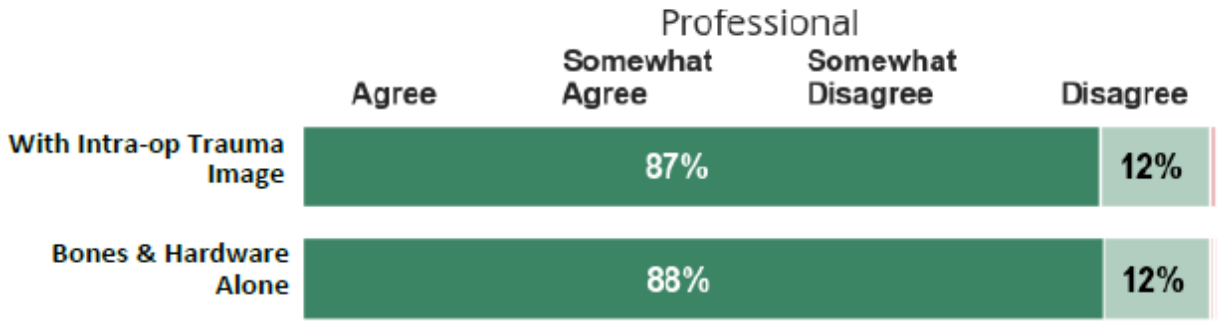


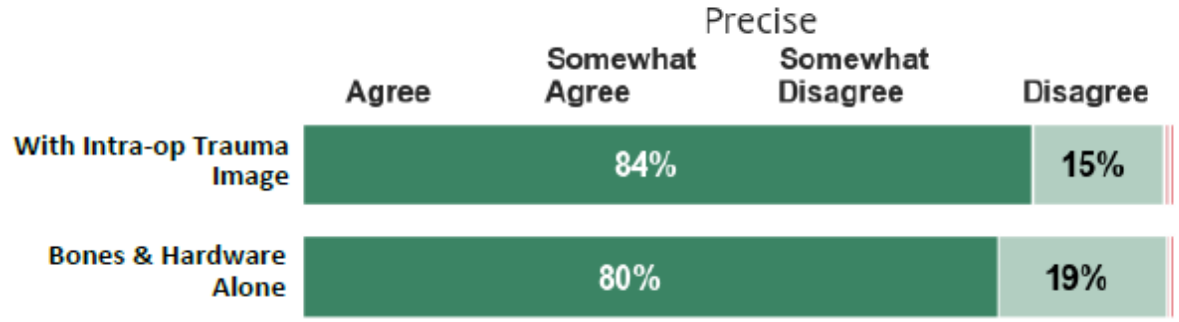


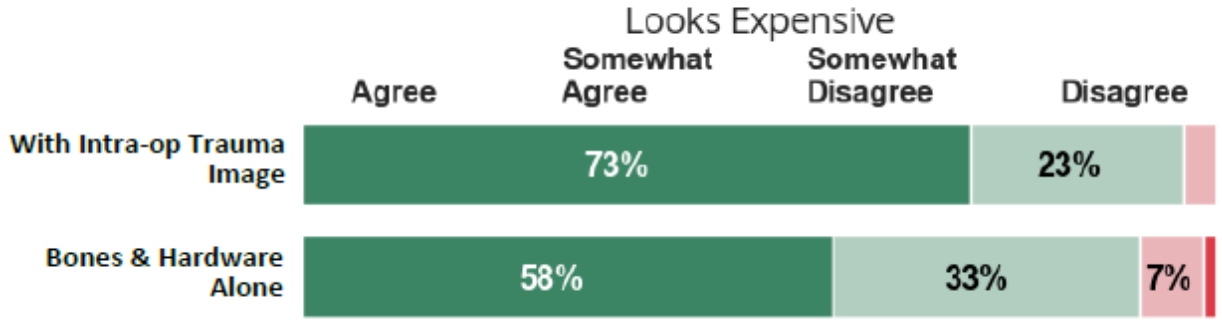

## ORIF of Fibula Fracture

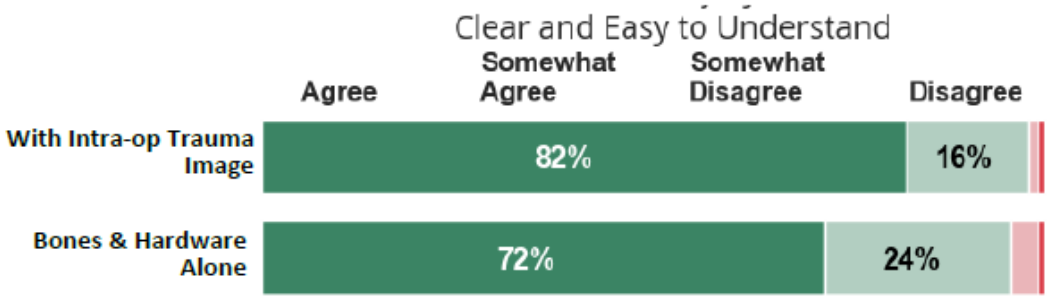


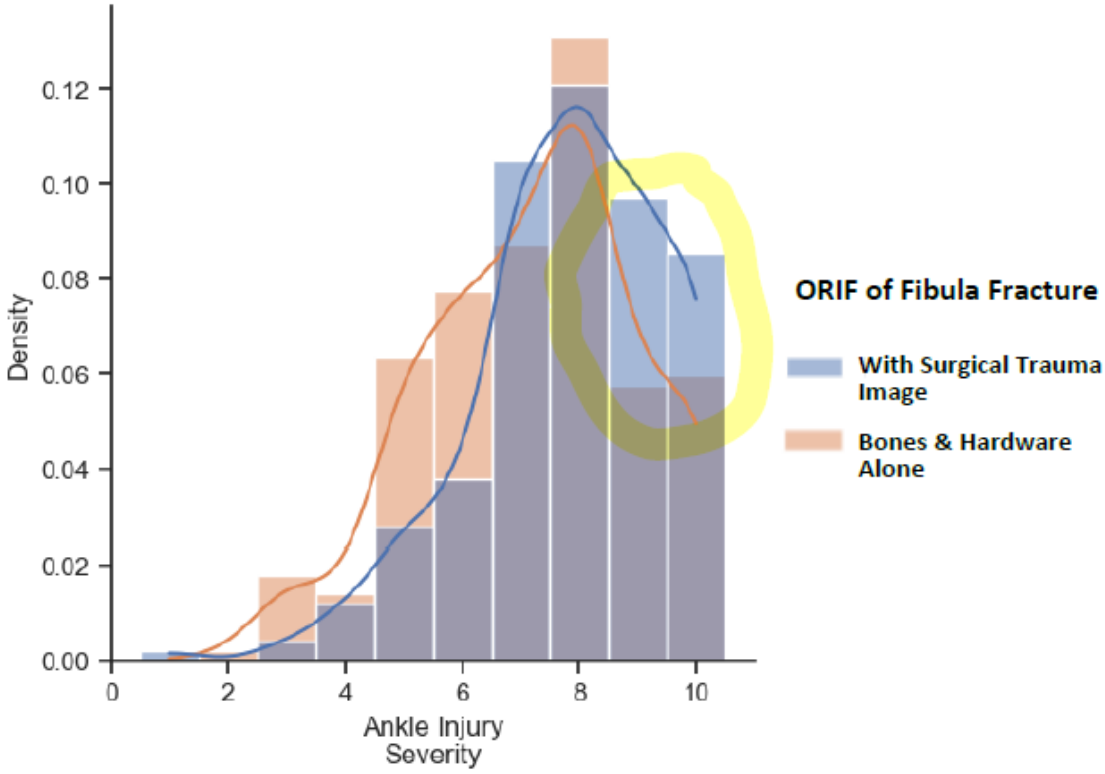

# Anterior Cervical Fusion

## With Cross-Section Showing Depth

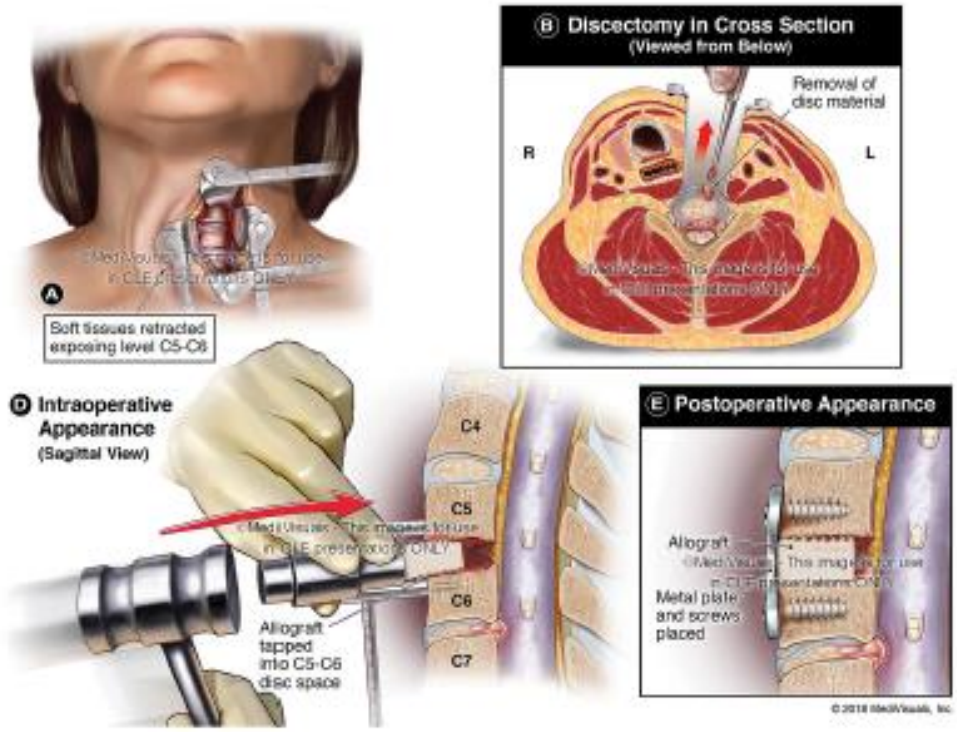


## Without Cross-Section

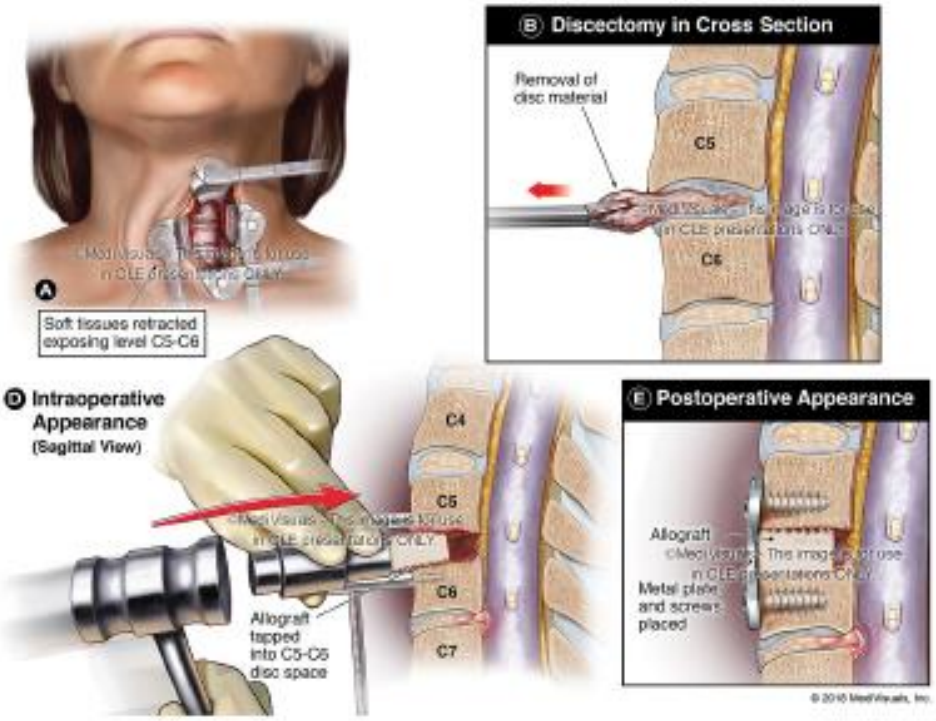

## Anterior Cervical Fusion

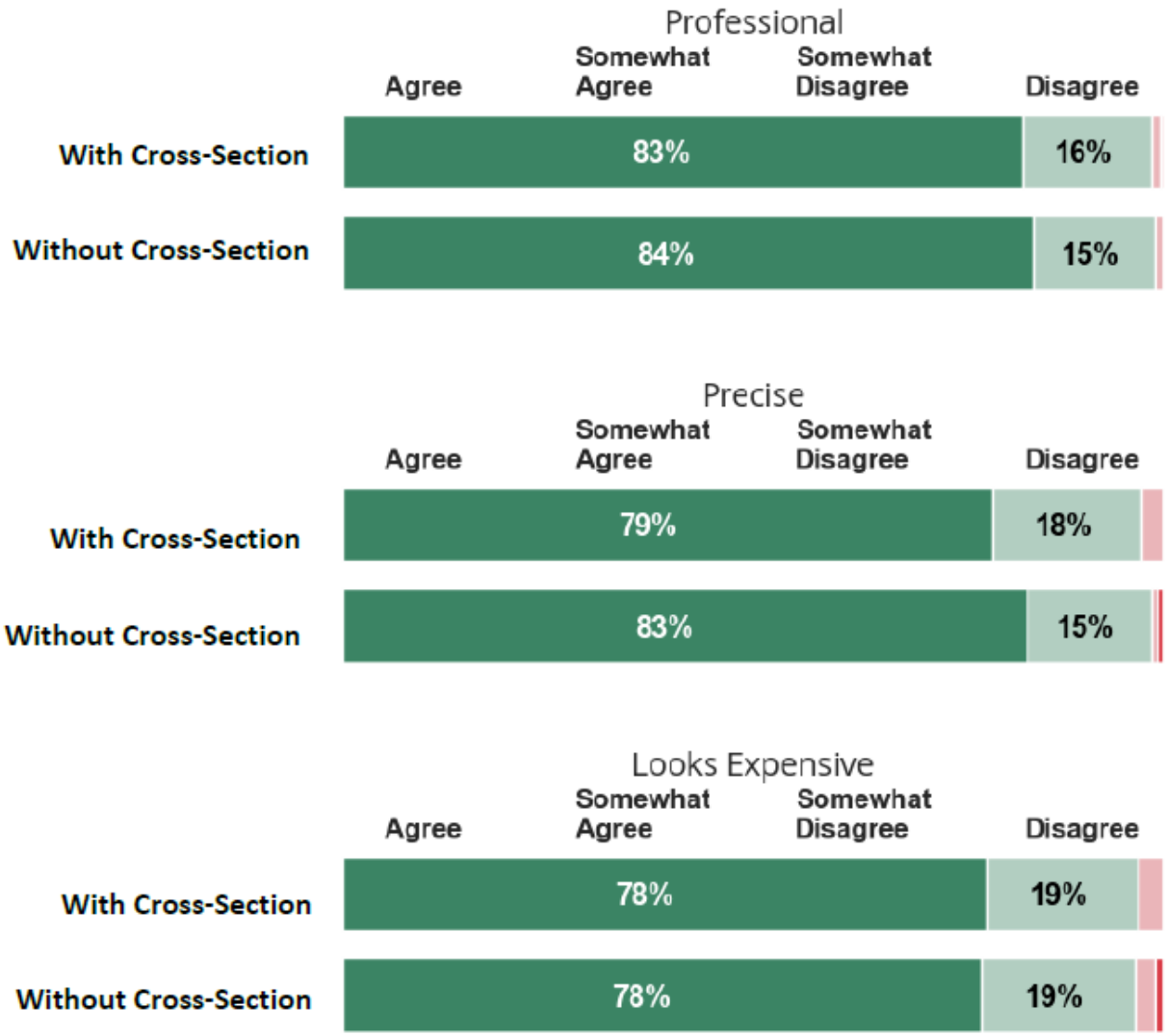

Note: These two graphs indicate that although jurors found the info clearer in the illustration without the cross-section, they found the severity of the surgical procedure to be greater in the image that showed the cross-section and depth of dissection (see the below two charts).

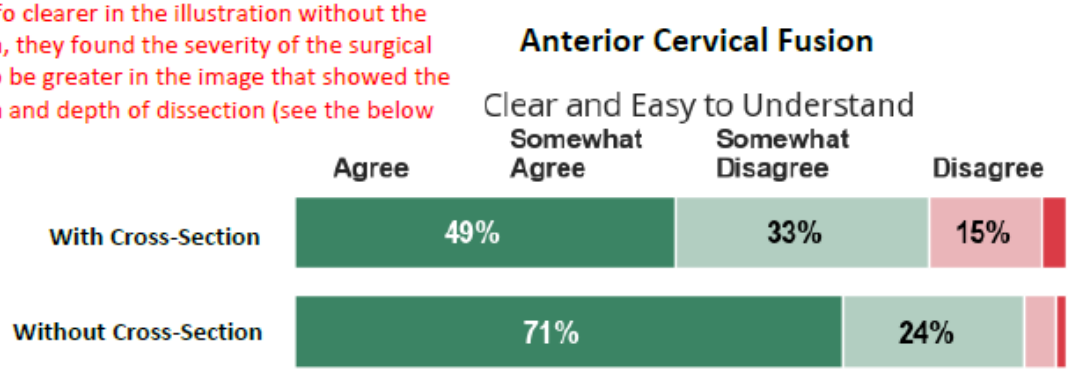


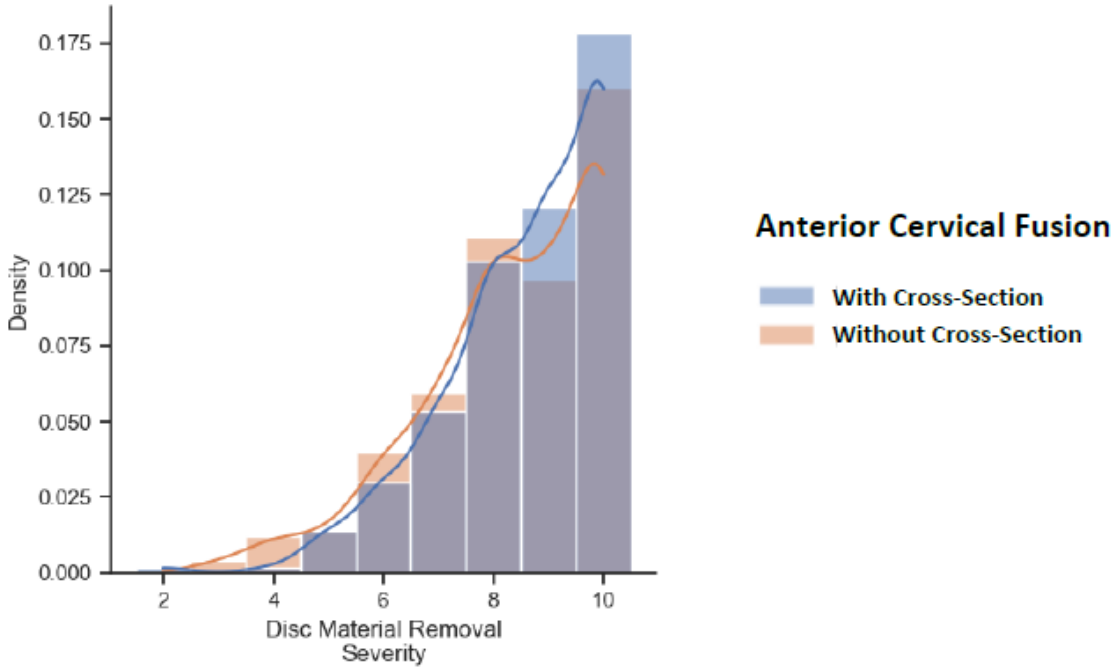

# Torso Injuries

**Anatomical Pose**

**Summary of Injuries**

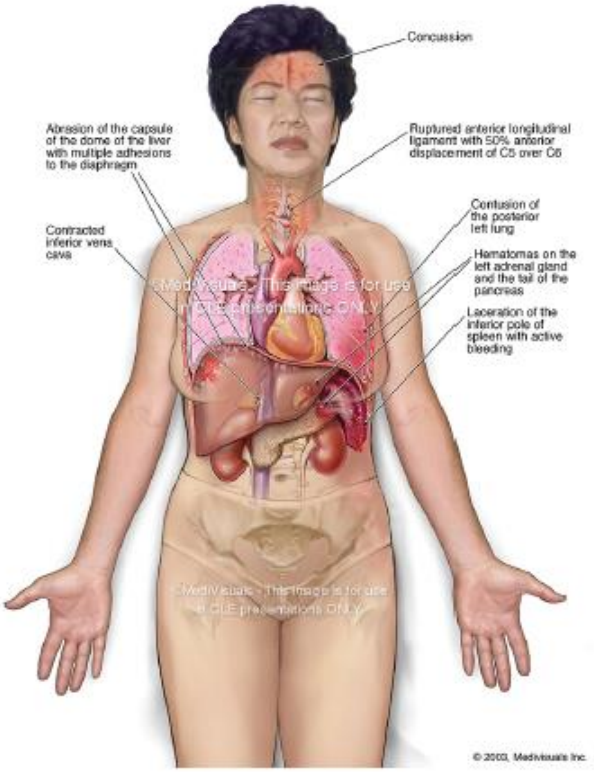


**More Natural Pose**

**Summary of Injuries**

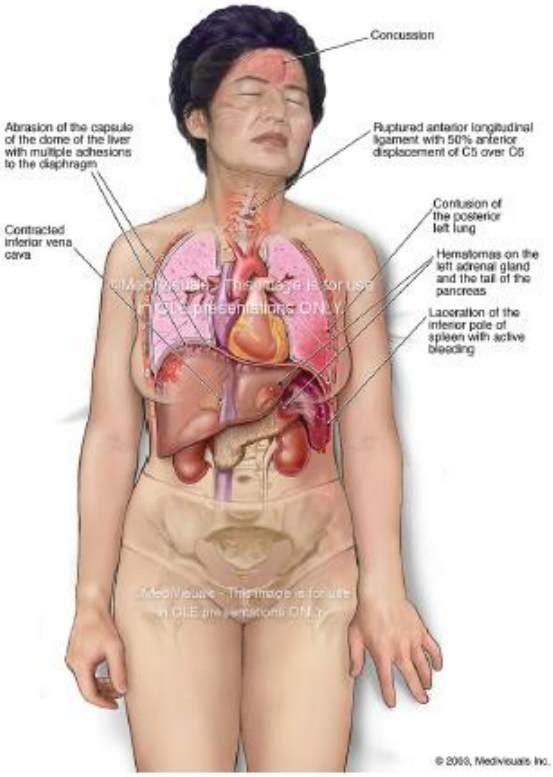


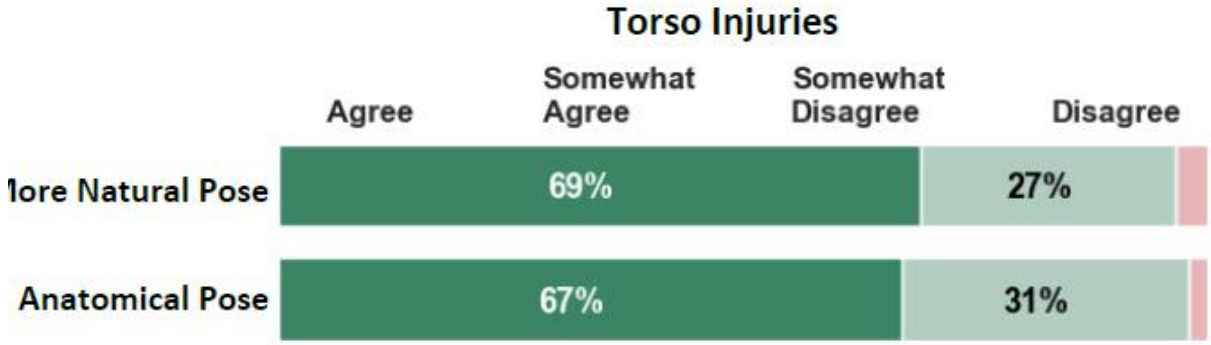

## Torso Injuries

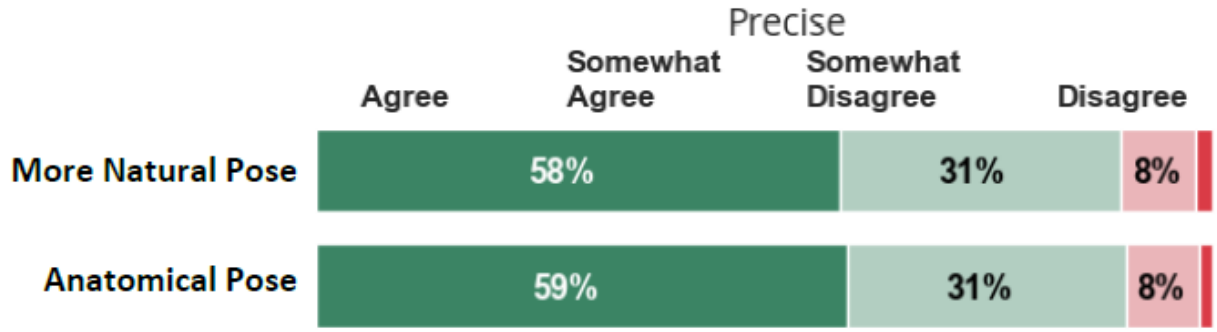


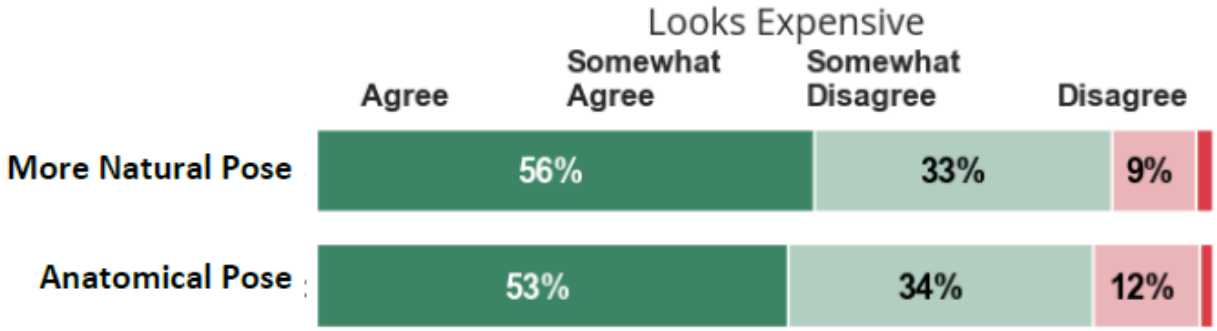


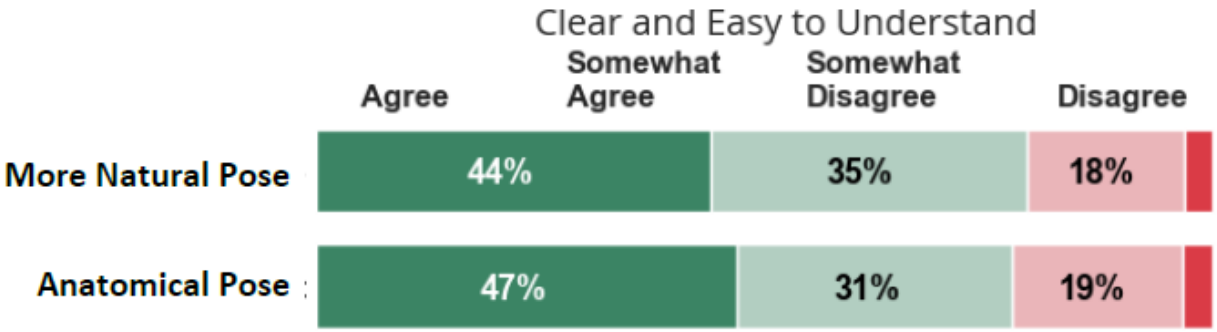

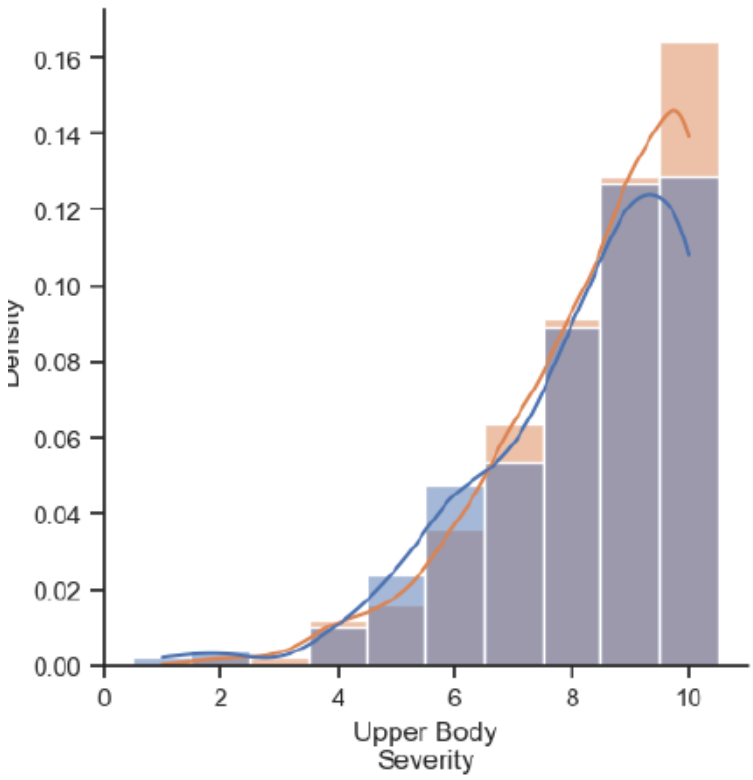


The results were suprising in this one. It was anticipated the figure in the more natural pose would be found more sympathetic than the one in the stiff anatomical pose and therefore jurors would feel the injuries were more severe.

**Torso Injuries**

**More Natural Pose**

**Anatomical Pose**

# Intra-op Plating of Fibula

## With hands

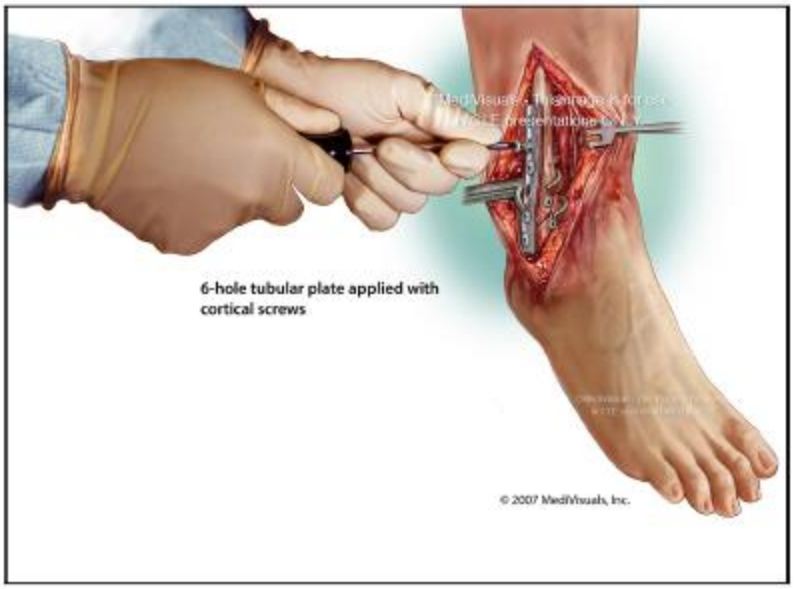


## Floating Instrument

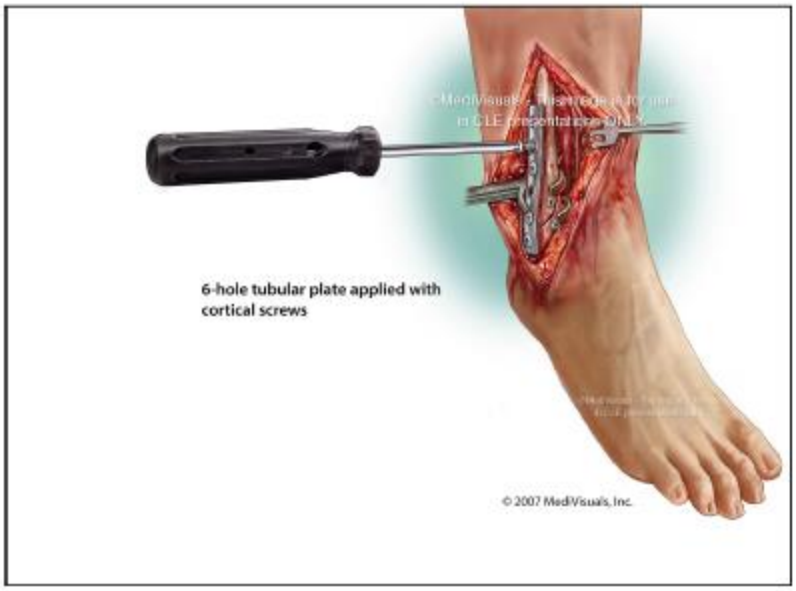

## Intra-op Plating of Fibula

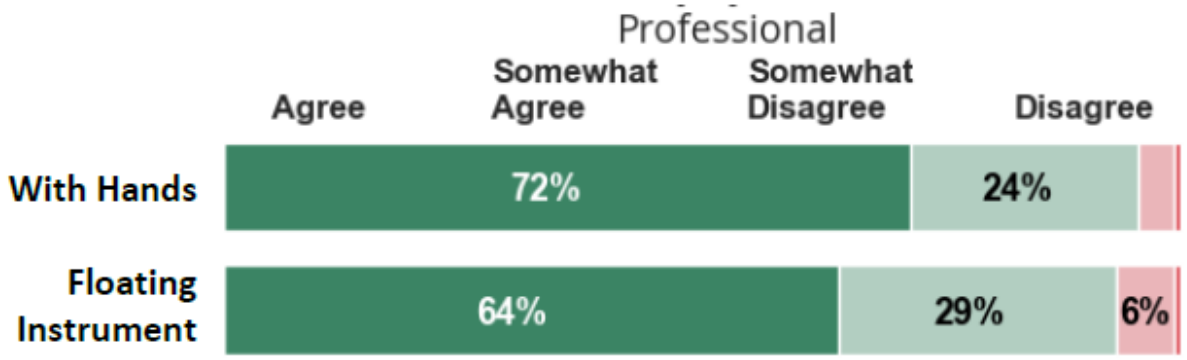


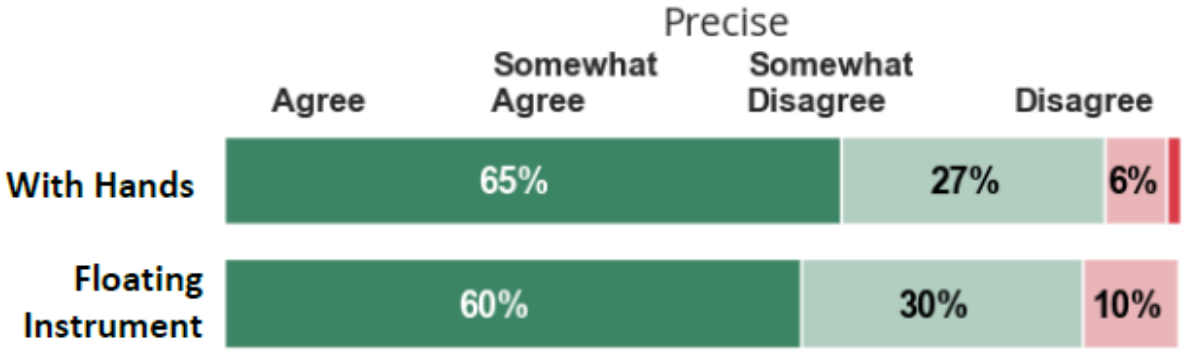


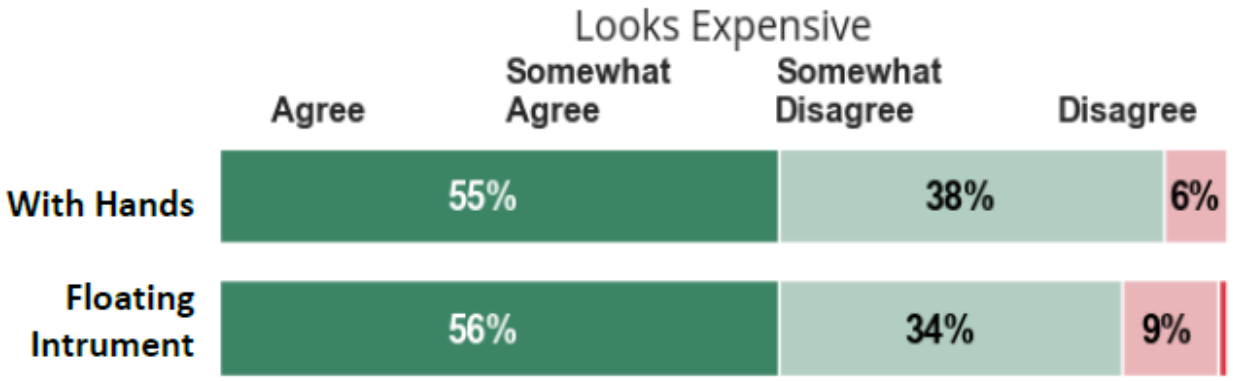

## Intra-op Plating of Fibula

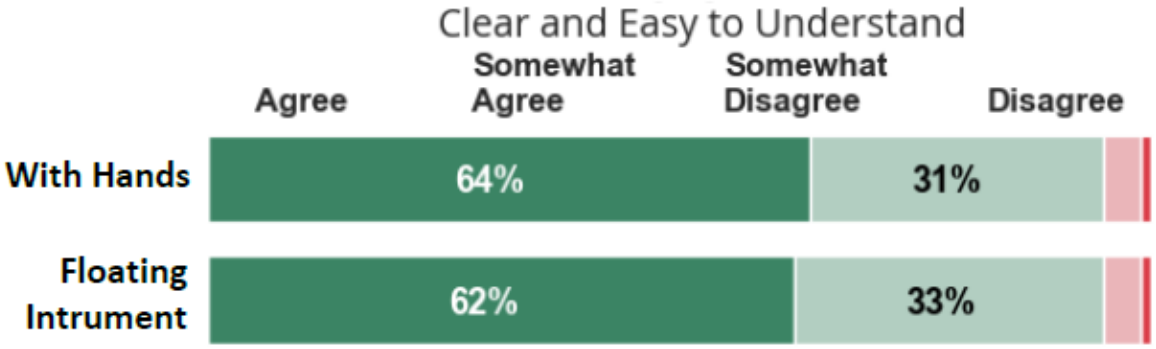


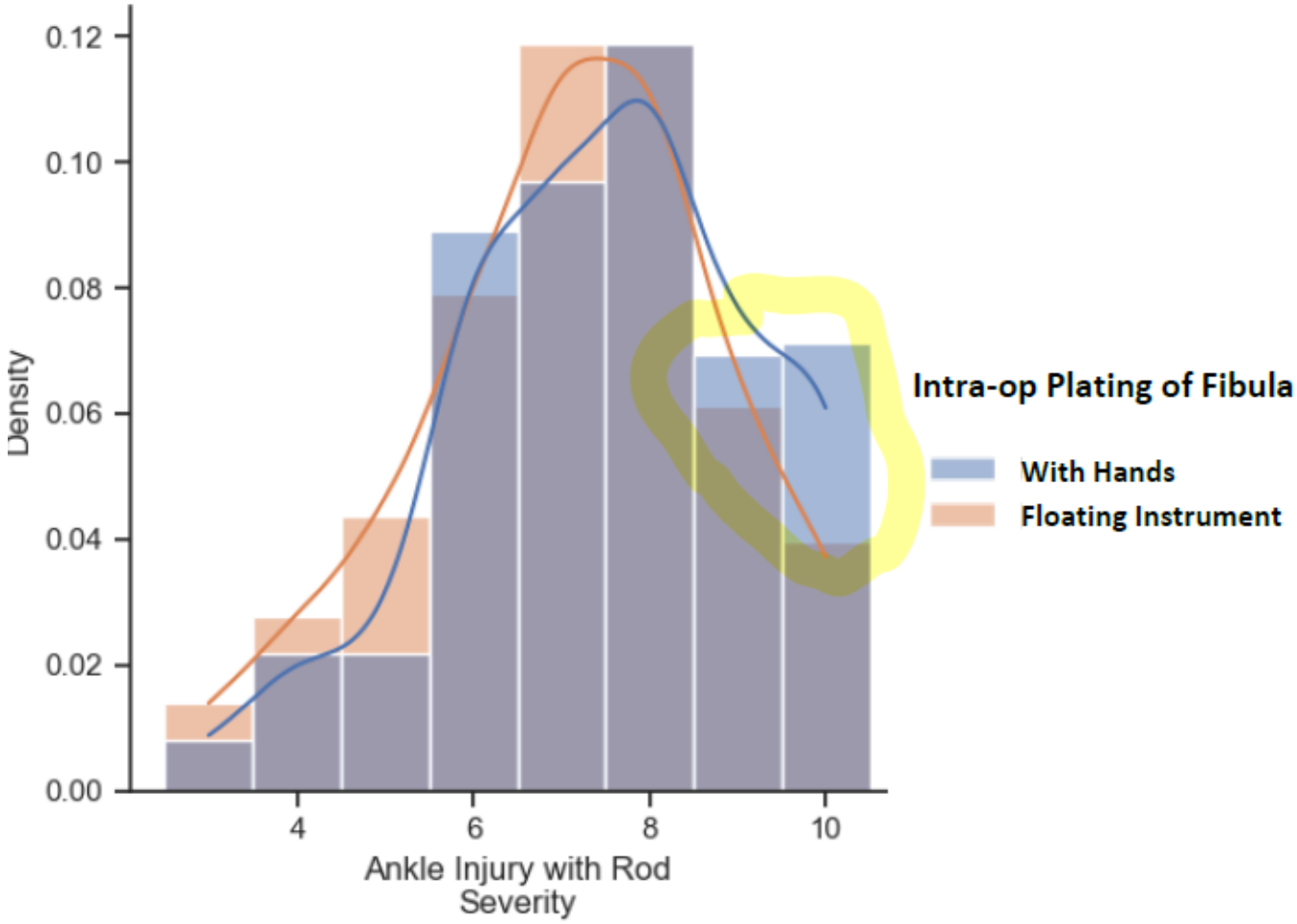

# Summary of Injuries - Floating v On Table

## Floating

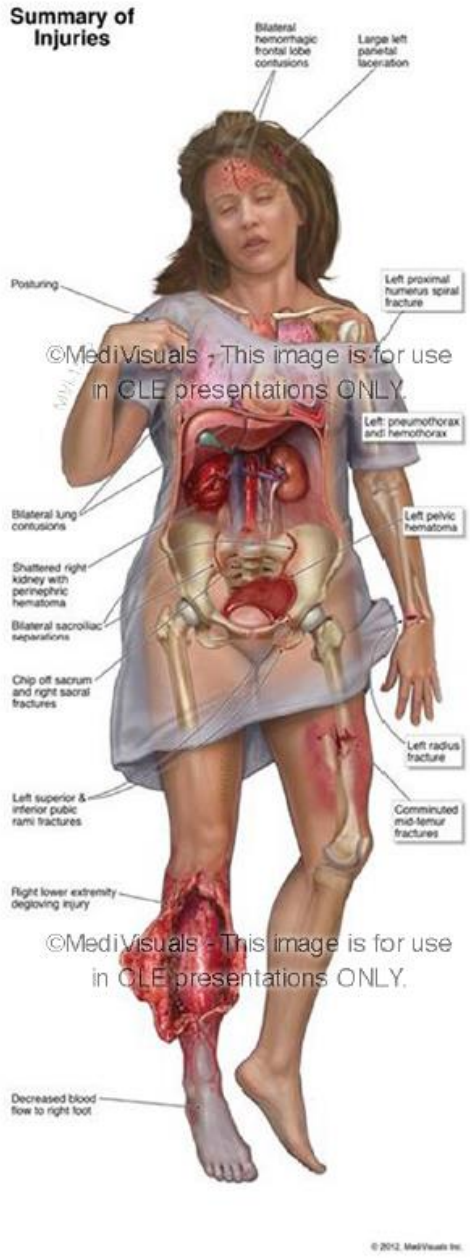


## On Table

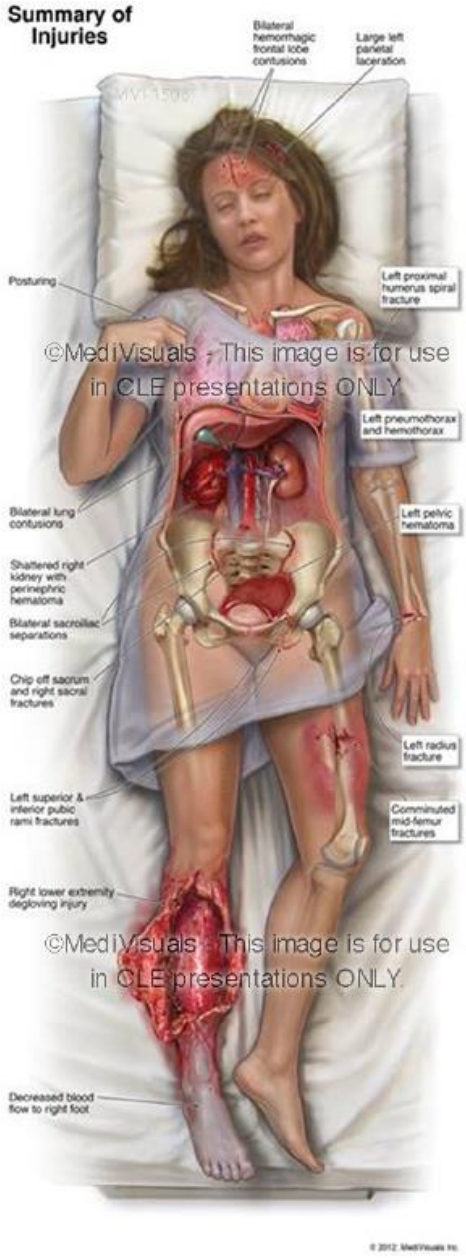

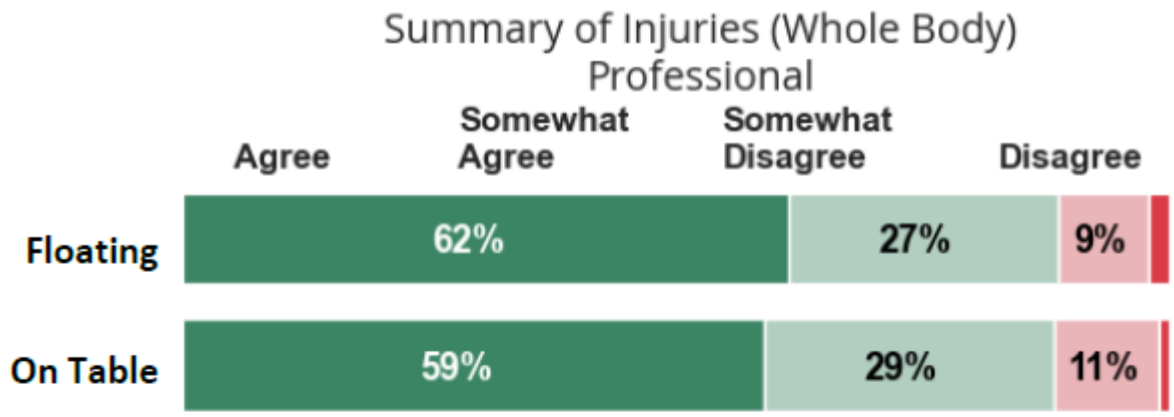
Summary of Injuries (Whole Body)
Professional
Agree
Somewhat Agree
Somewhat Disagree
Disagree
Floating
62%
27%
9%
On Table
59%
29%
11%

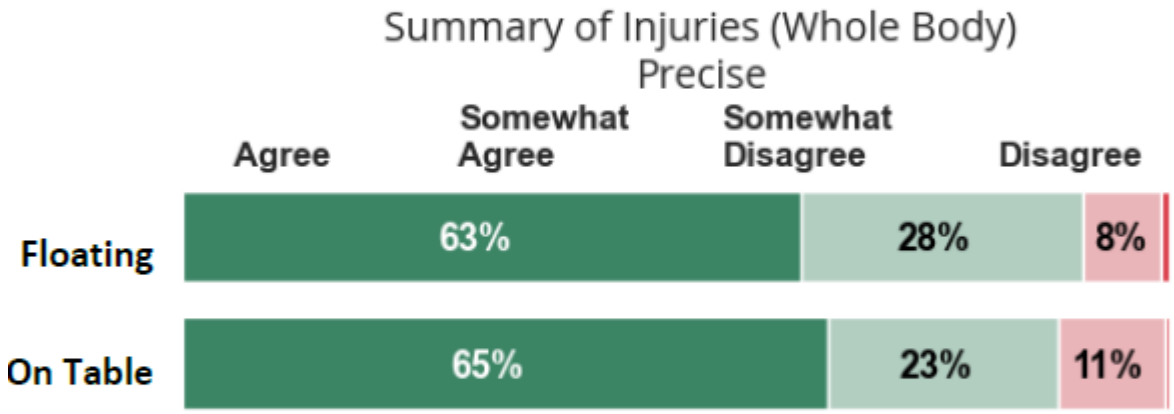
Summary of Injuries (Whole Body)
Precise
Agree
Somewhat Agree
Somewhat Disagree
Disagree
Floating
63%
28%
8%
On Table
65%
23%
11%

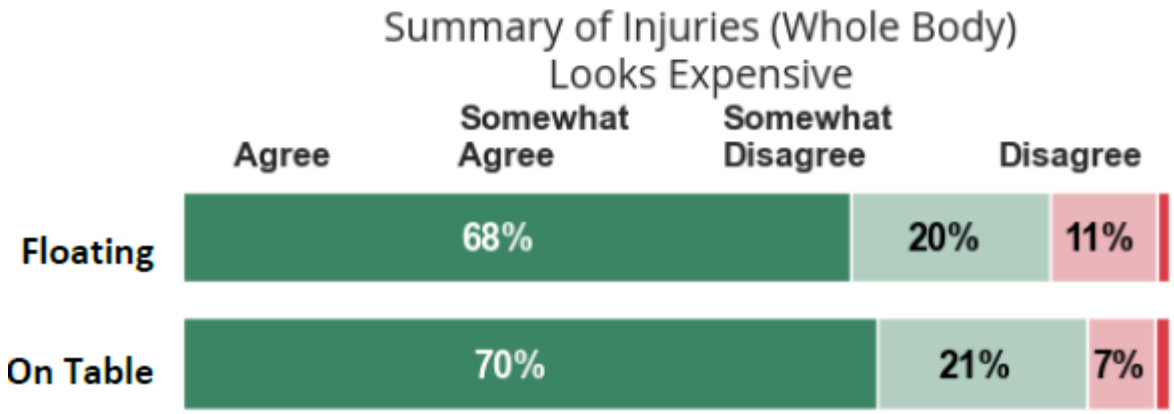
Summary of Injuries (Whole Body)
Looks Expensive
Agree
Somewhat Agree
Somewhat Disagree
Disagree
Floating
68%
20%
11%
On Table
70%
21%
7%

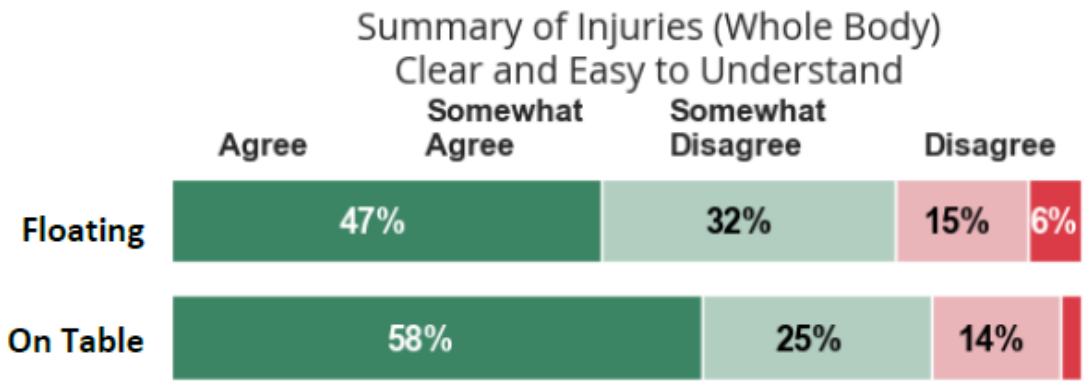
Summary of Injuries (Whole Body)
Clear and Easy to Understand
Agree
Somewhat Agree
Somewhat Disagree
Disagree
Floating
47%
32%
15%
6%
On Table
58%
25%
14%

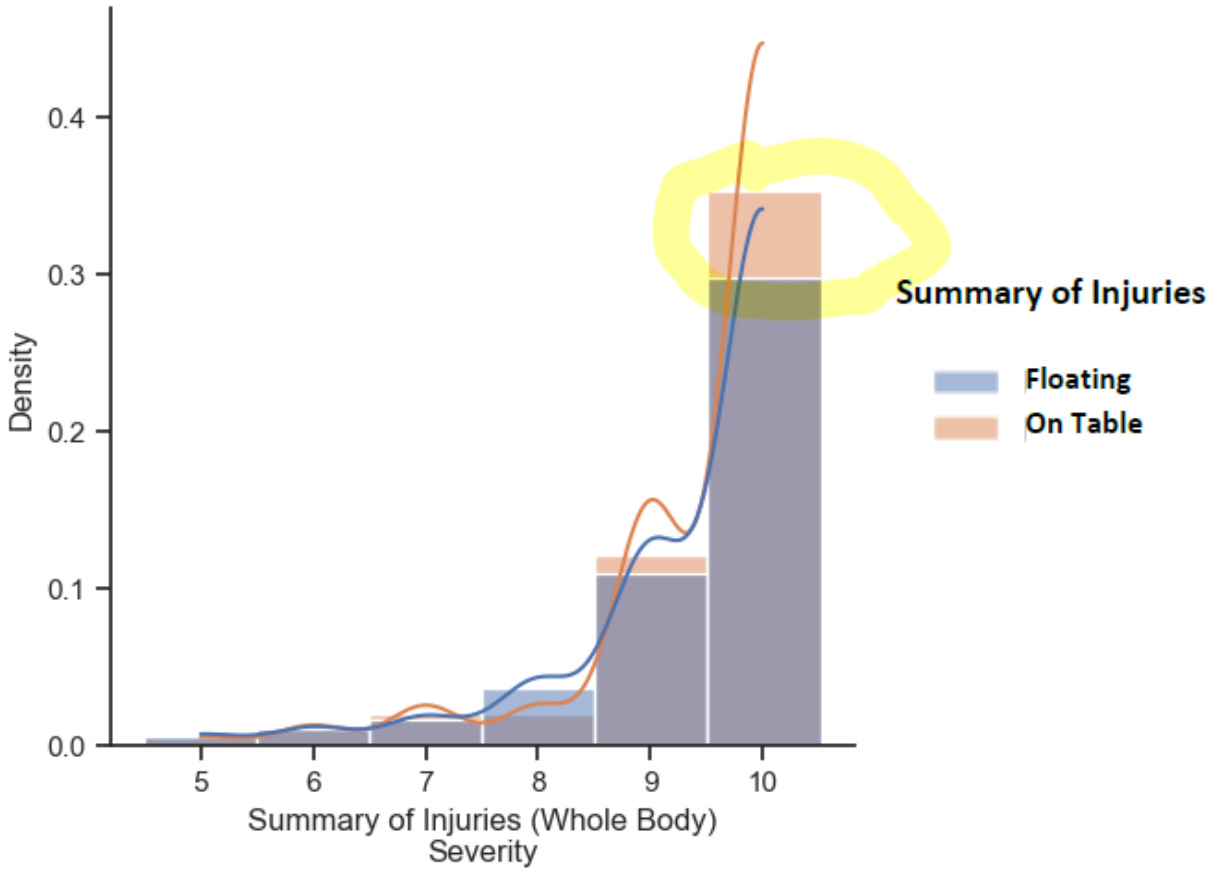
Density
0.0
0.1
0.2
0.3
0.4
5
6
7
8
9
10
Summary of Injuries (Whole Body)
Severity
Summary of Injuries
Floating
On Table

# Femur Rodding Animation

## Simplified


## With Appropriate Emphasis

## Femur Rodding Animation

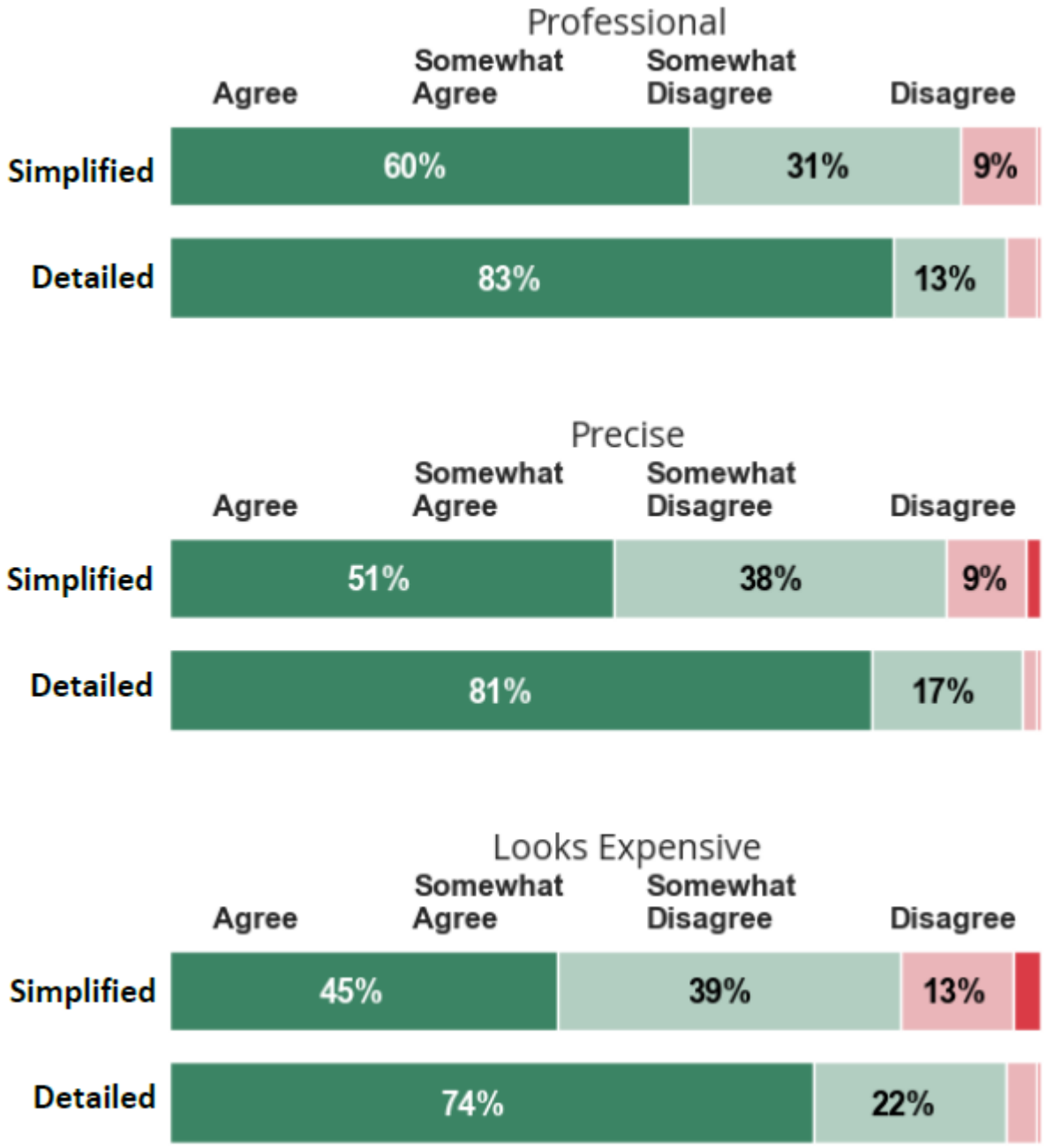

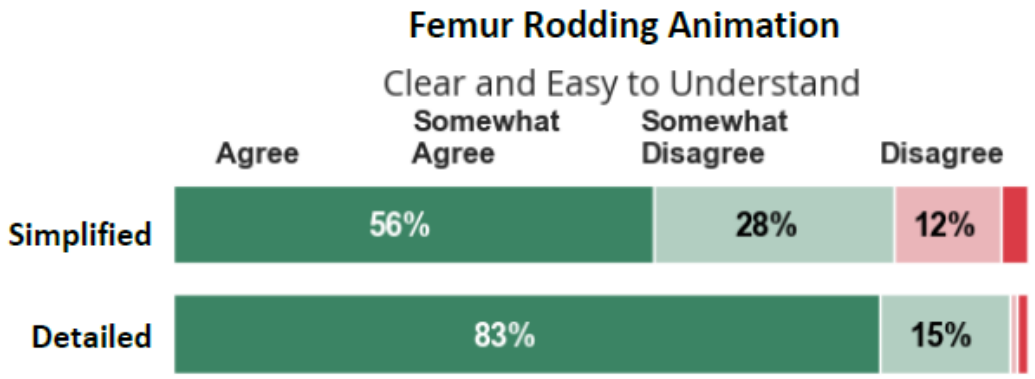
Femur Rodding Animation
Clear and Easy to Understand
Agree
Somewhat Agree
Somewhat Disagree
Disagree
Simplified
56%
28%
12%
Detailed
83%
15%

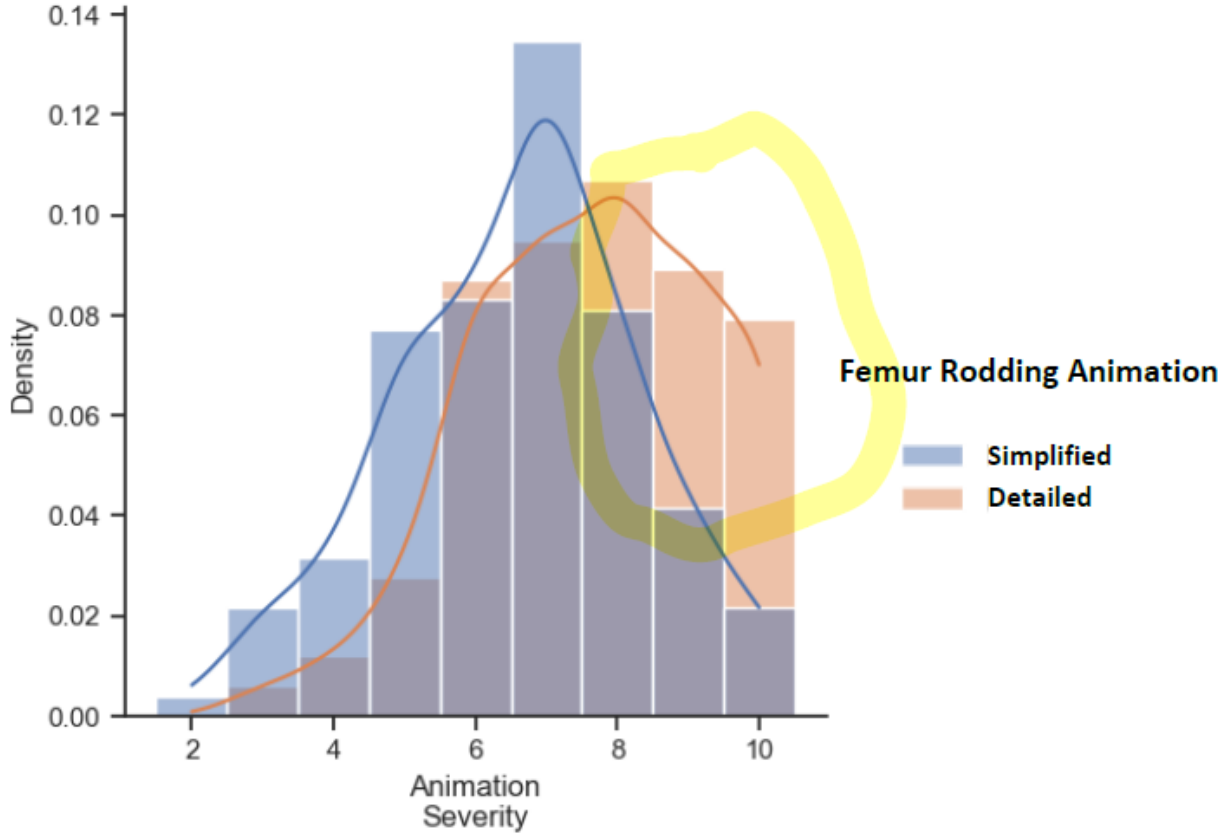
0.14
0.12
0.10
0.08
0.06
0.04
0.02
0.00
Density
2
4
6
8
10
Animation Severity
Femur Rodding Animation
Simplified
Detailed

# Rodding of Tibia

**Hands Stabilizing Lower Leg**

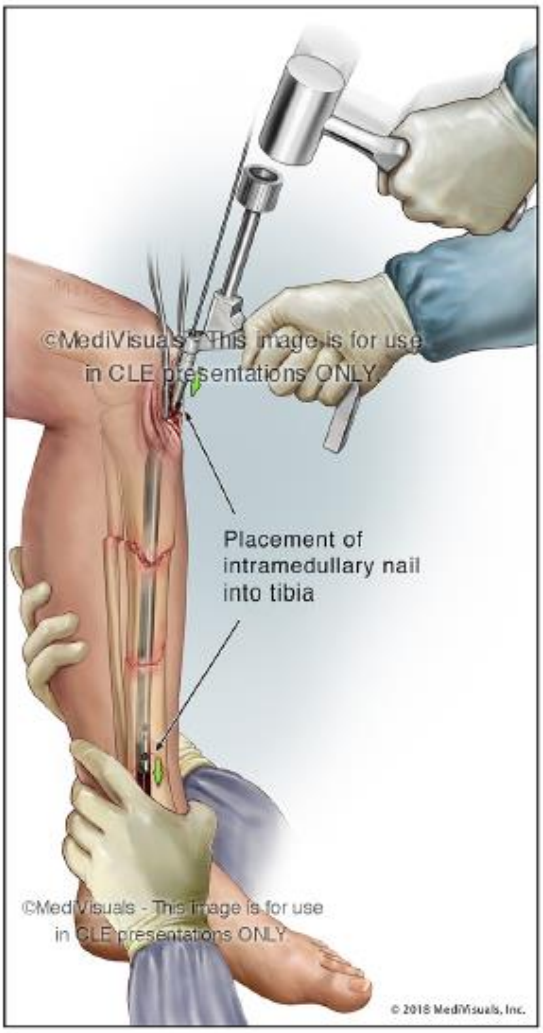


**No Lower Hands**

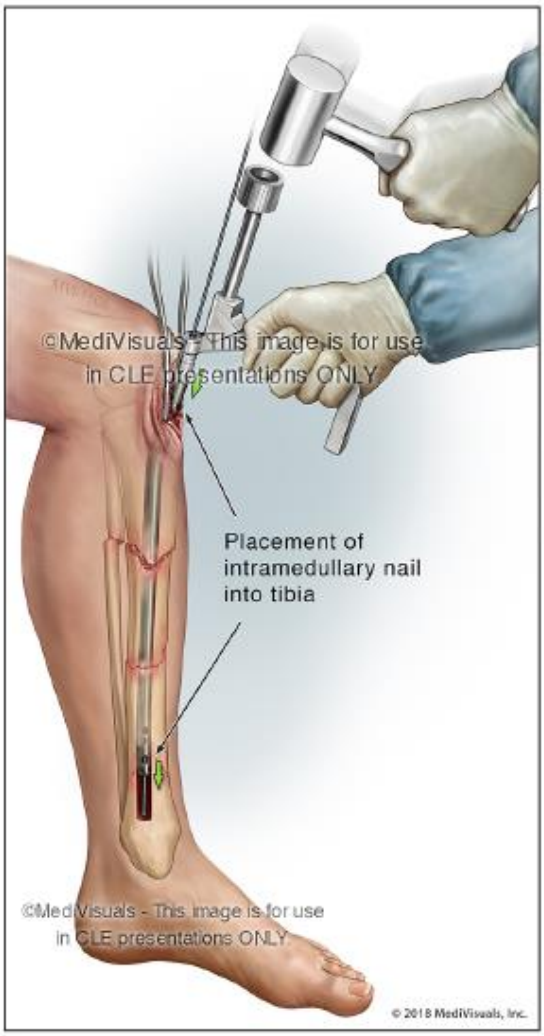

## Rodding of Tibia

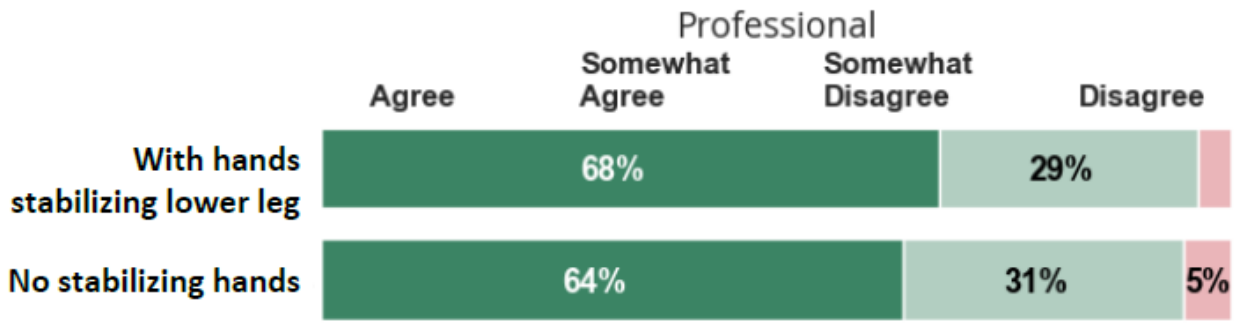


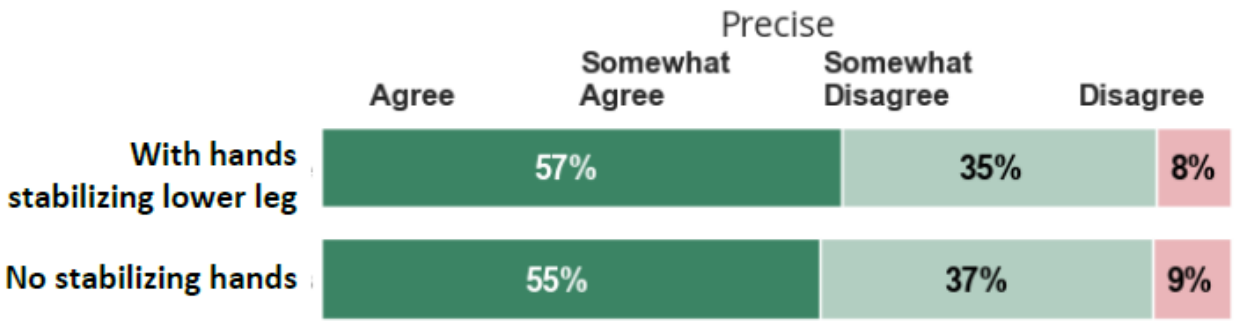


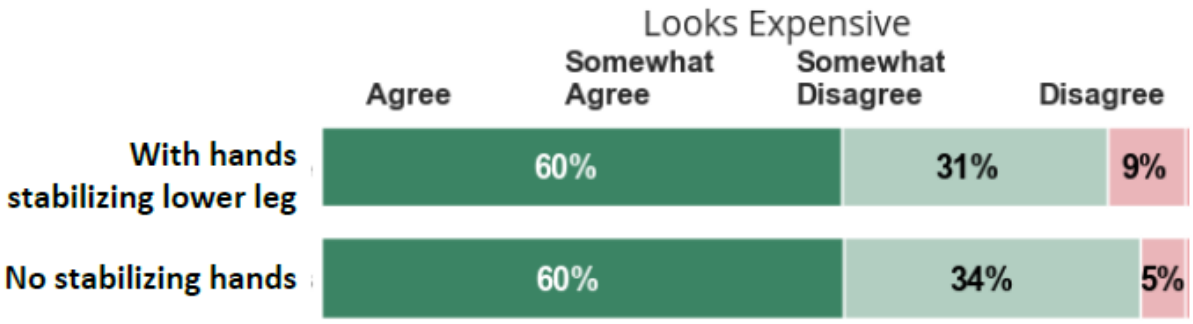

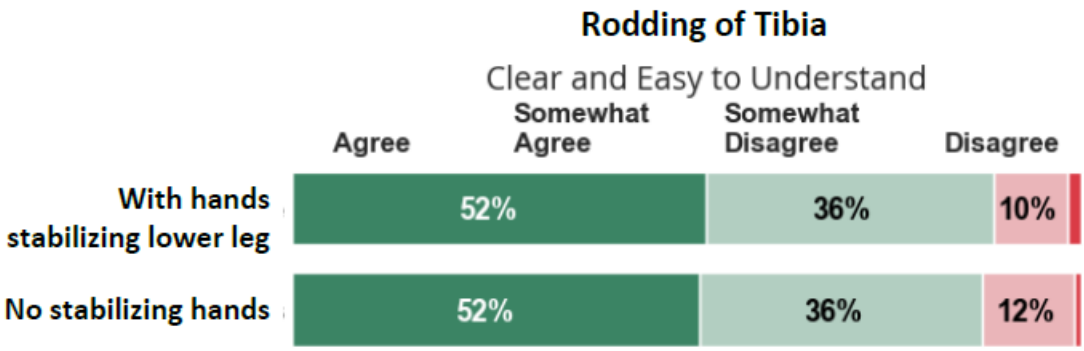
Rodding of Tibia
Clear and Easy to Understand
Agree
Somewhat Agree
Somewhat Disagree
Disagree
With hands stabilizing lower leg
52%
36%
10%
No stabilizing hands
52%
36%
12%

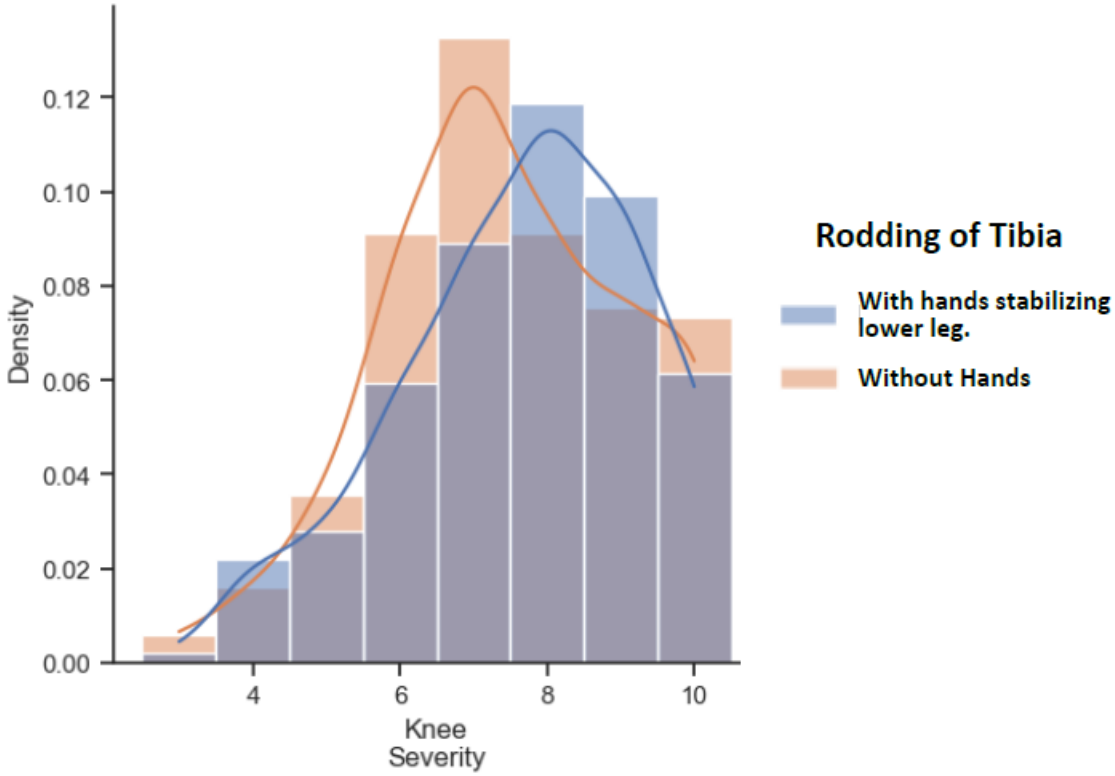
Density
0.12
0.10
0.08
0.06
0.04
0.02
0.00
4
6
8
10
Knee Severity
Rodding of Tibia
With hands stabilizing lower leg.
Without Hands

# Degloving of Calf

**No Blood**


**With Blood**

## Degloving of Calf

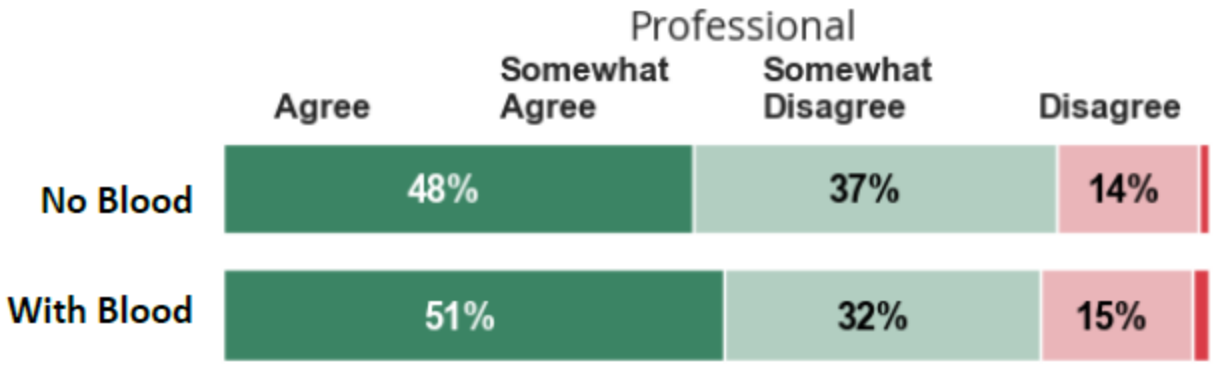


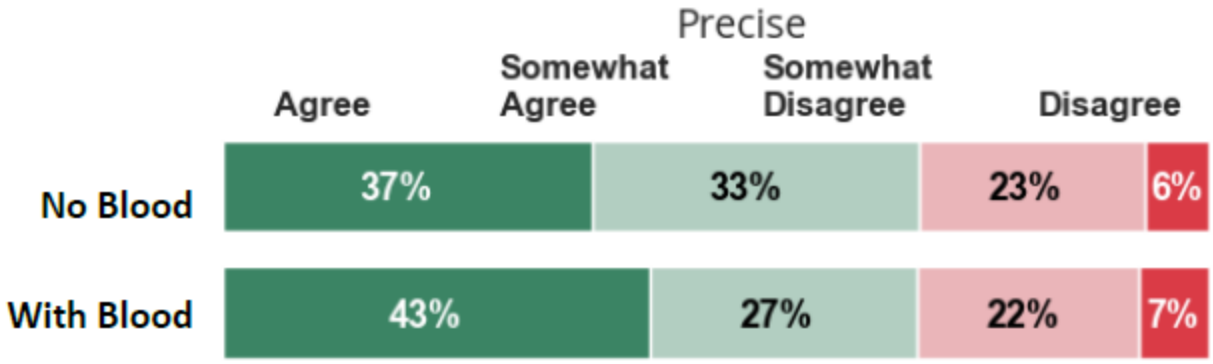


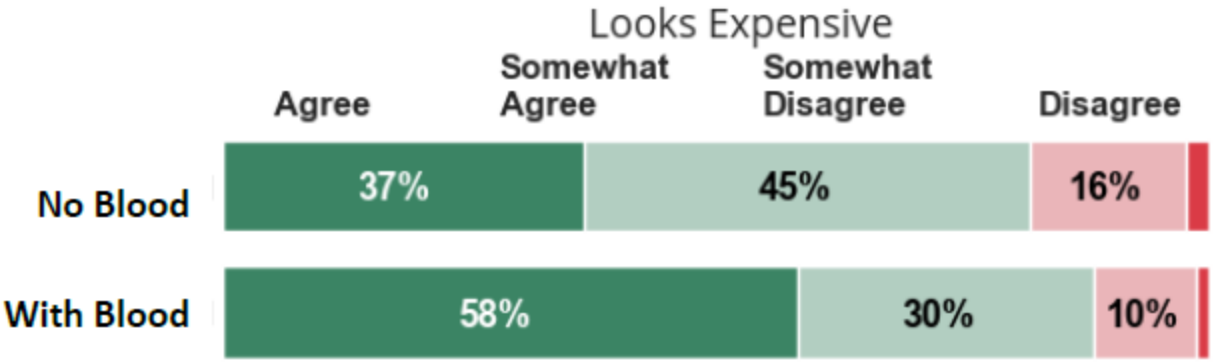

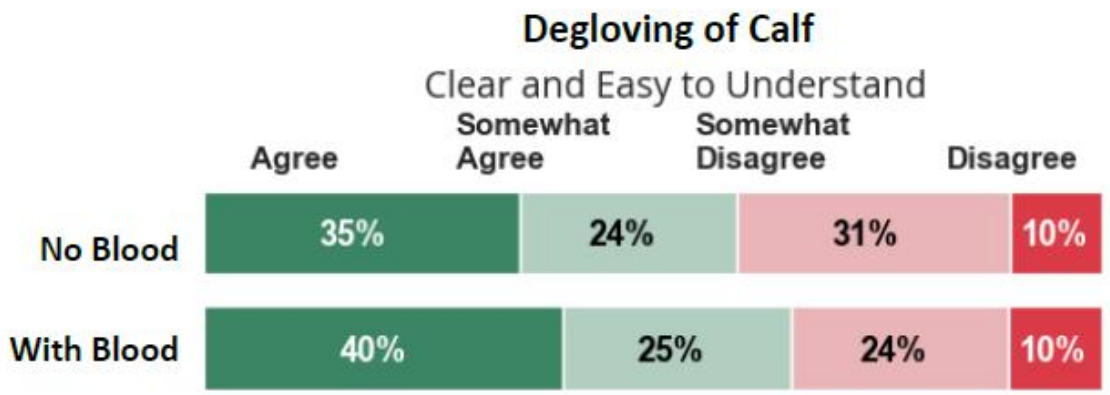
Degloving of Calf
Clear and Easy to Understand
Agree
Somewhat Agree
Somewhat Disagree
Disagree
No Blood
35%
24%
31%
10%
With Blood
40%
25%
24%
10%

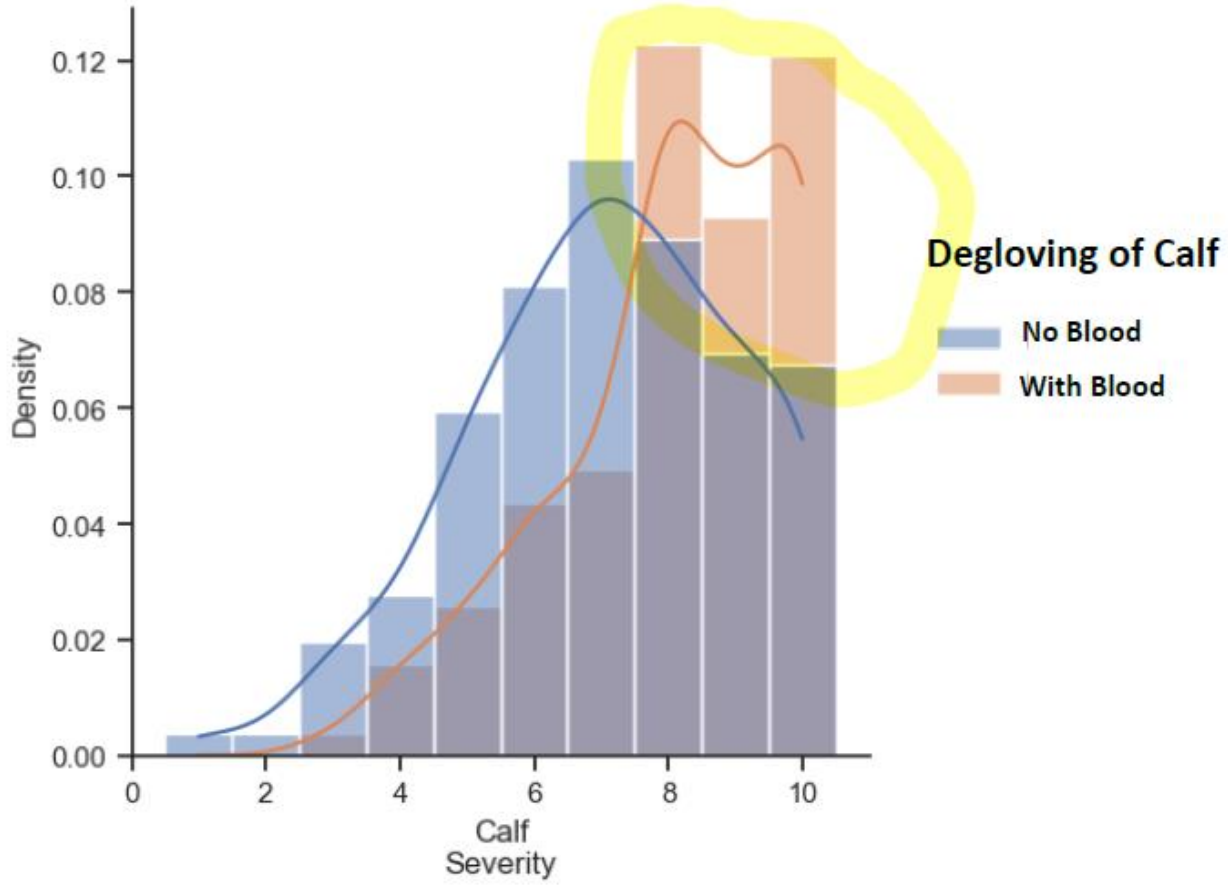
Density
0.12
0.10
0.08
0.06
0.04
0.02
0.00
0
2
4
6
8
10
Calf Severity
Degloving of Calf
No Blood
With Blood

# Summary of Injuries

**Realistic / Professional**

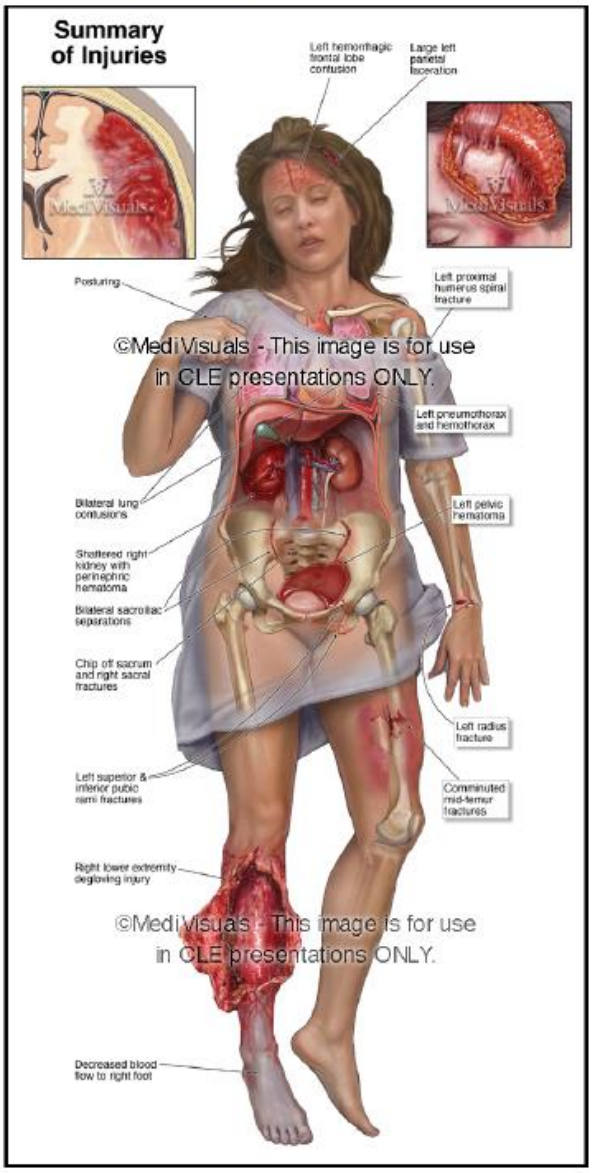


**Diagrammatic / Amateurish**

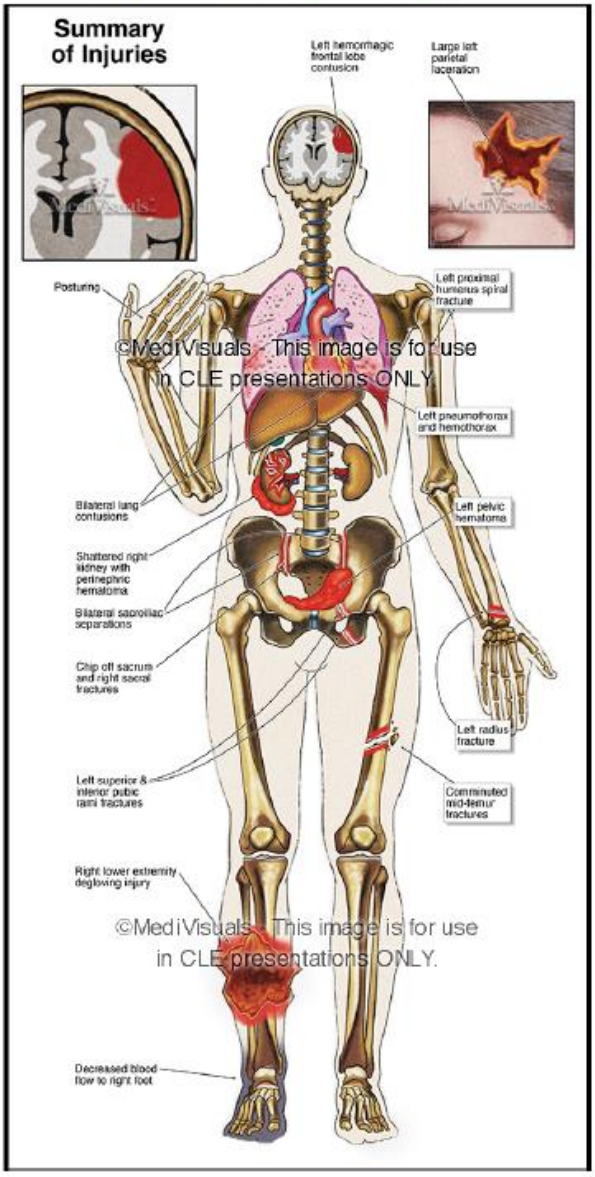

## Summary of Injuries

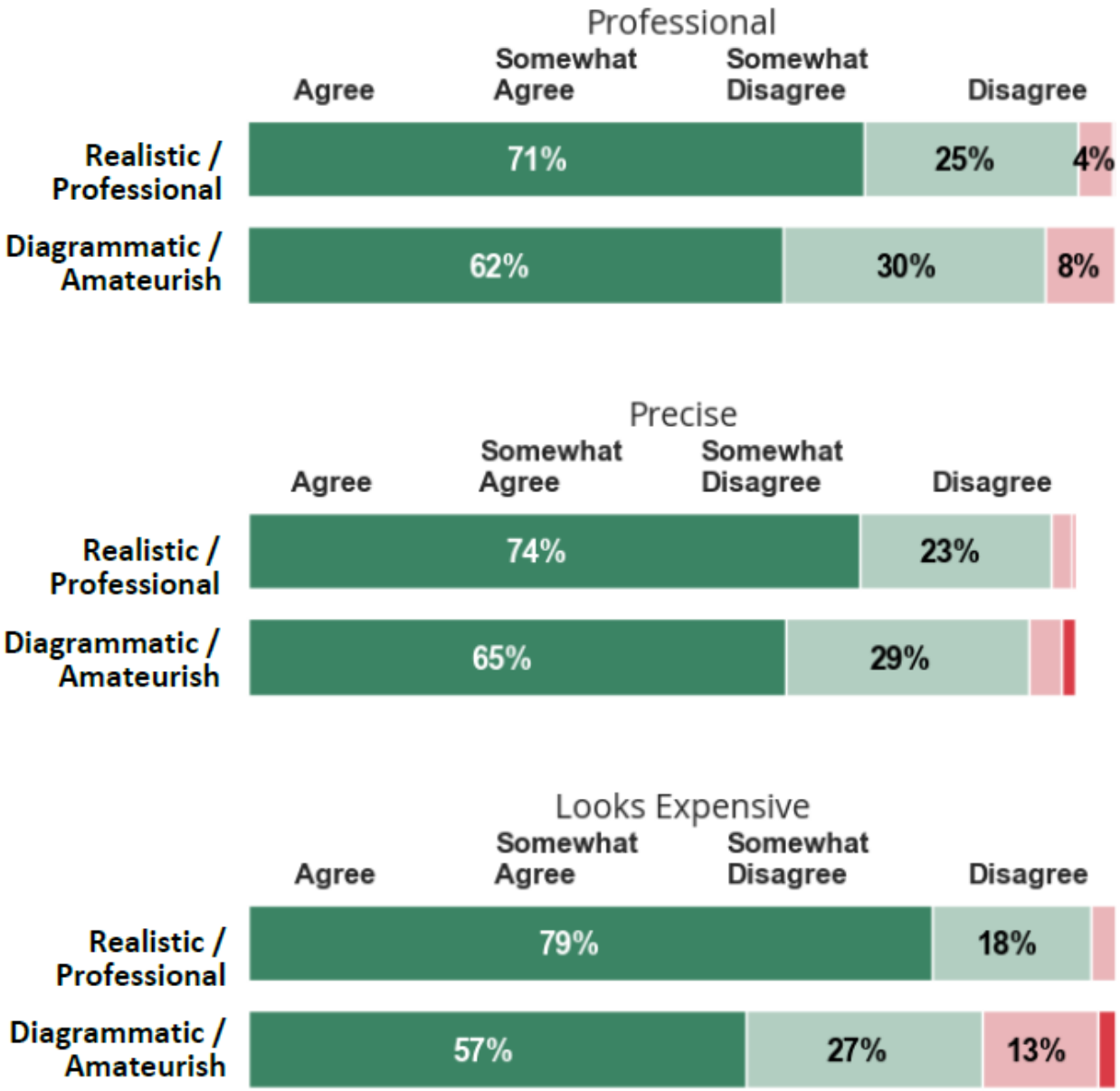

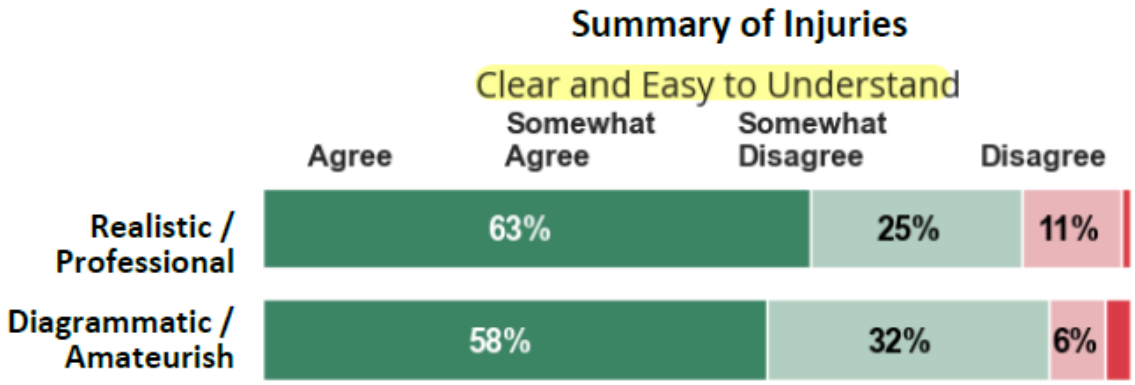
Summary of Injuries
Clear and Easy to Understand
Agree
Somewhat Agree
Somewhat Disagree
Disagree
Realistic / Professional
63%
25%
11%
Diagrammatic / Amateurish
58%
32%
6%

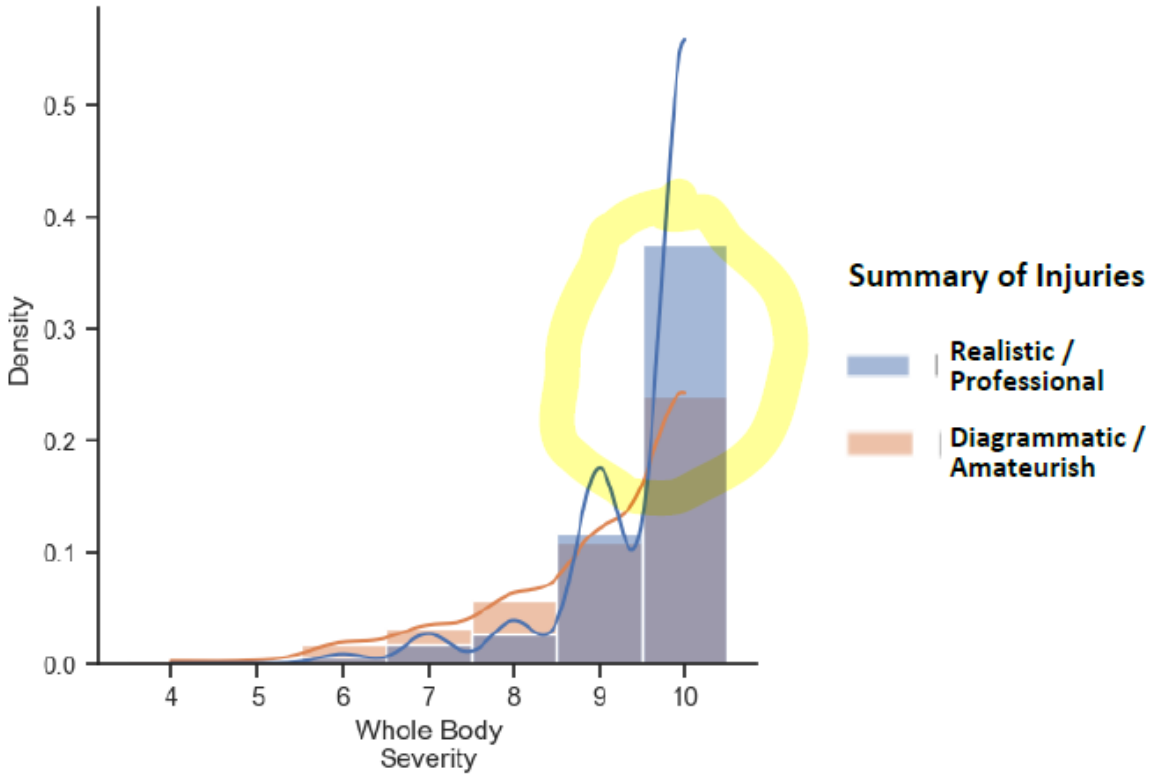
Density
0.0
0.1
0.2
0.3
0.4
0.5
4
5
6
7
8
9
10
Whole Body Severity
Summary of Injuries
Realistic / Professional
Diagrammatic / Amateurish

## Summary of Injuries

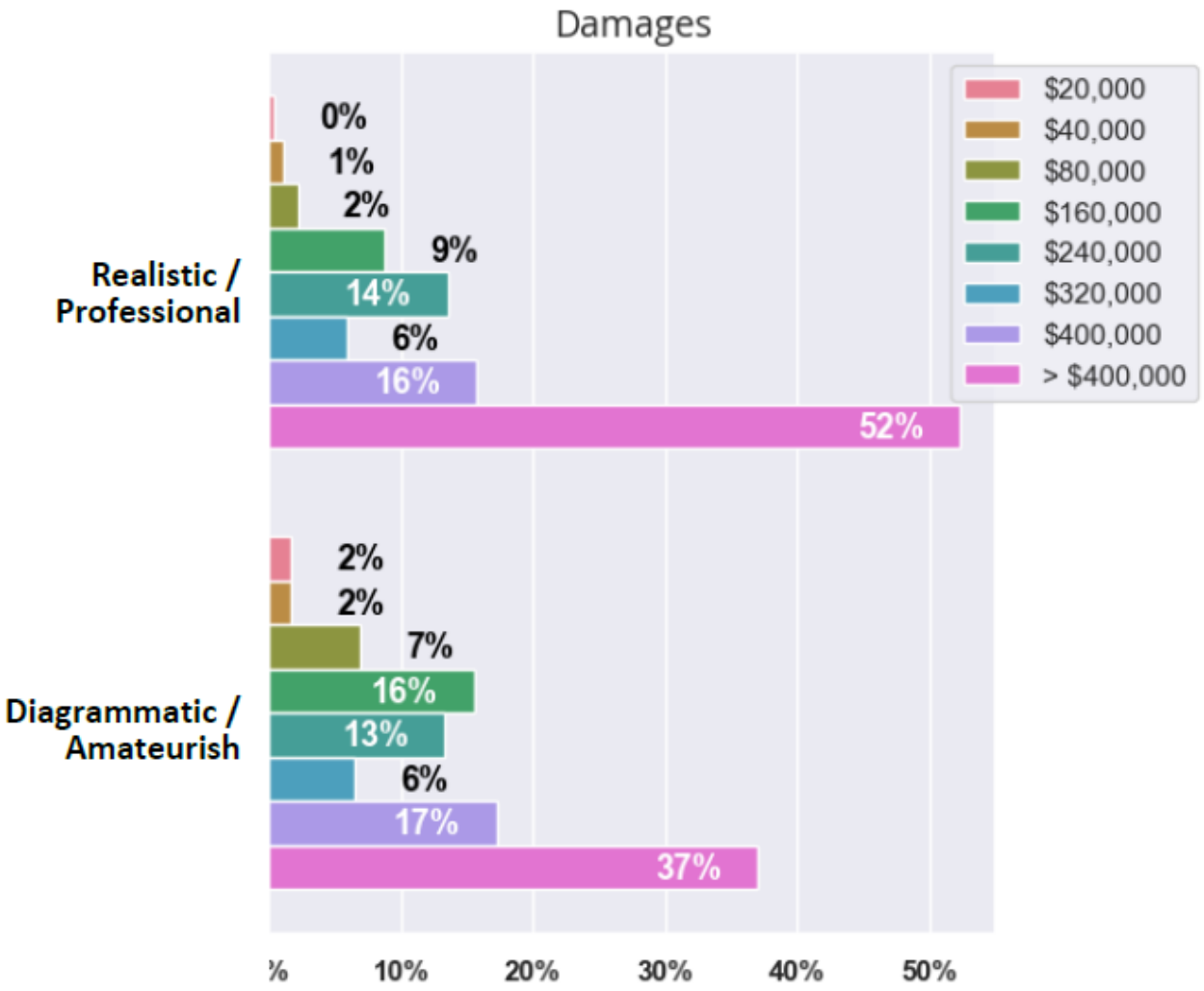

# Spine Scans - Sagittal

## Scan Alone


Im: 9/17
Sagittal View

## Scan with "Colorization"

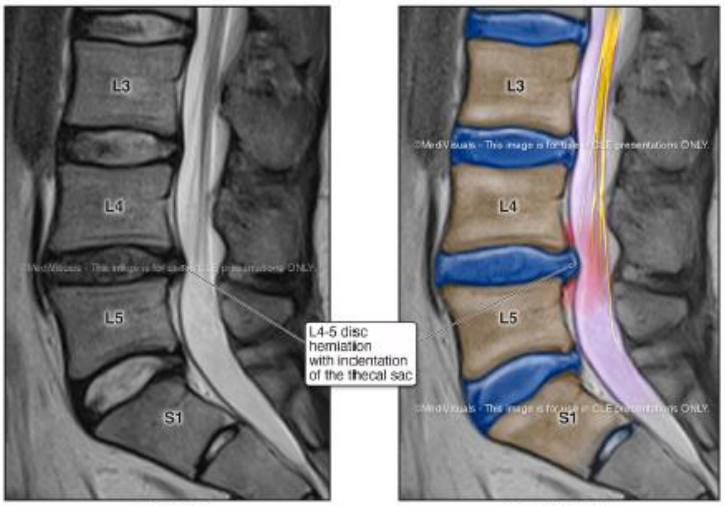


Im: 9/17

Sagittal View

## Scan with Illustration

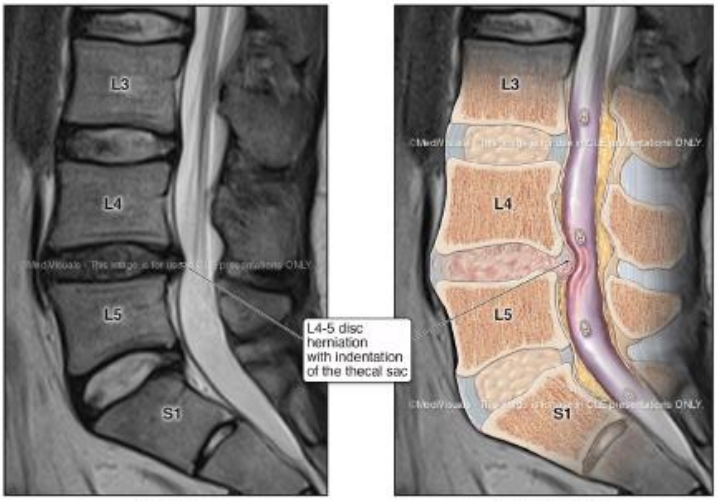


Im: 9/17

Sagittal View

## Spine Scan - Sagittal

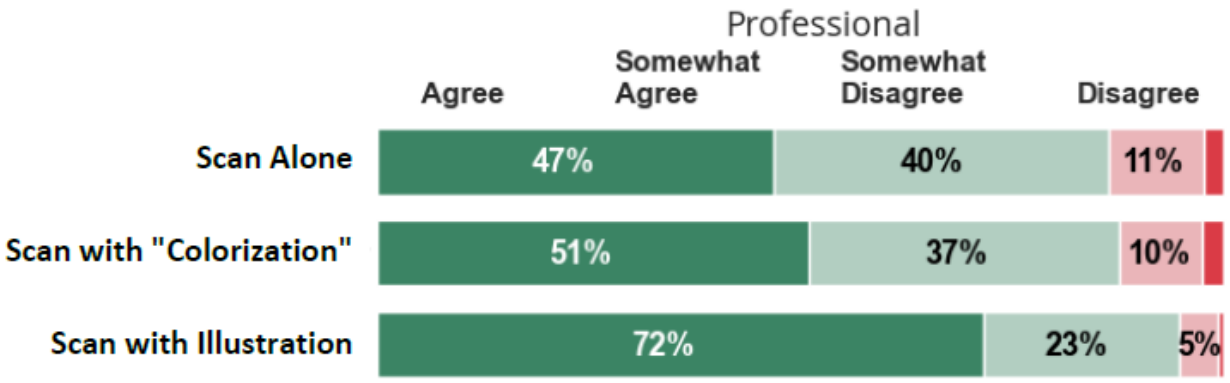


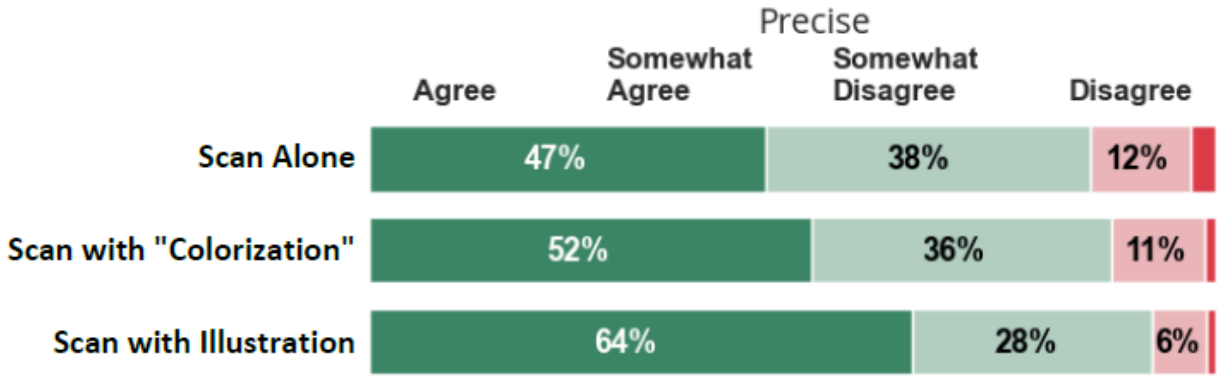


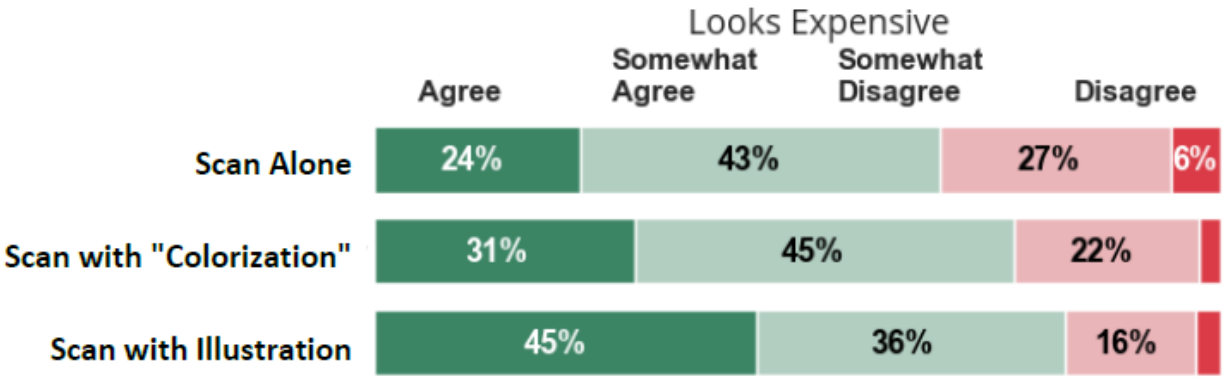

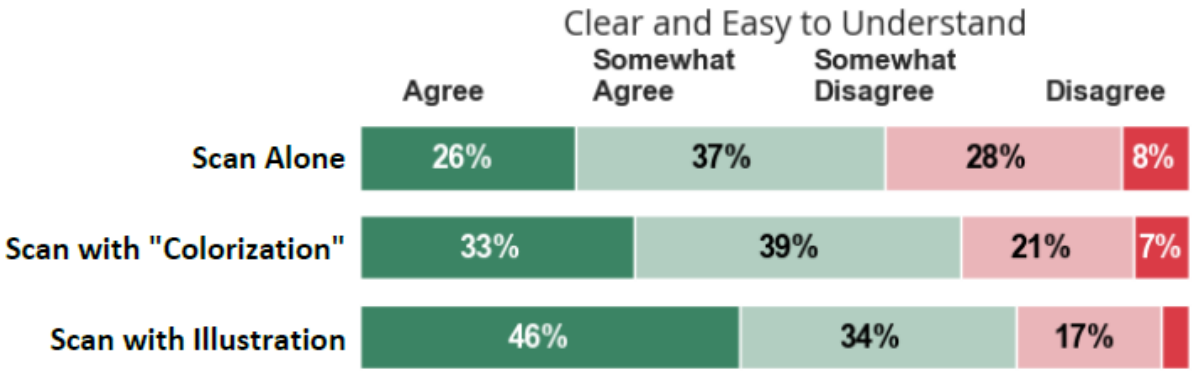
Clear and Easy to Understand
Agree
Somewhat Agree
Somewhat Disagree
Disagree
Scan Alone
26%
37%
28%
8%
Scan with "Colorization"
33%
39%
21%
7%
Scan with Illustration
46%
34%
17%

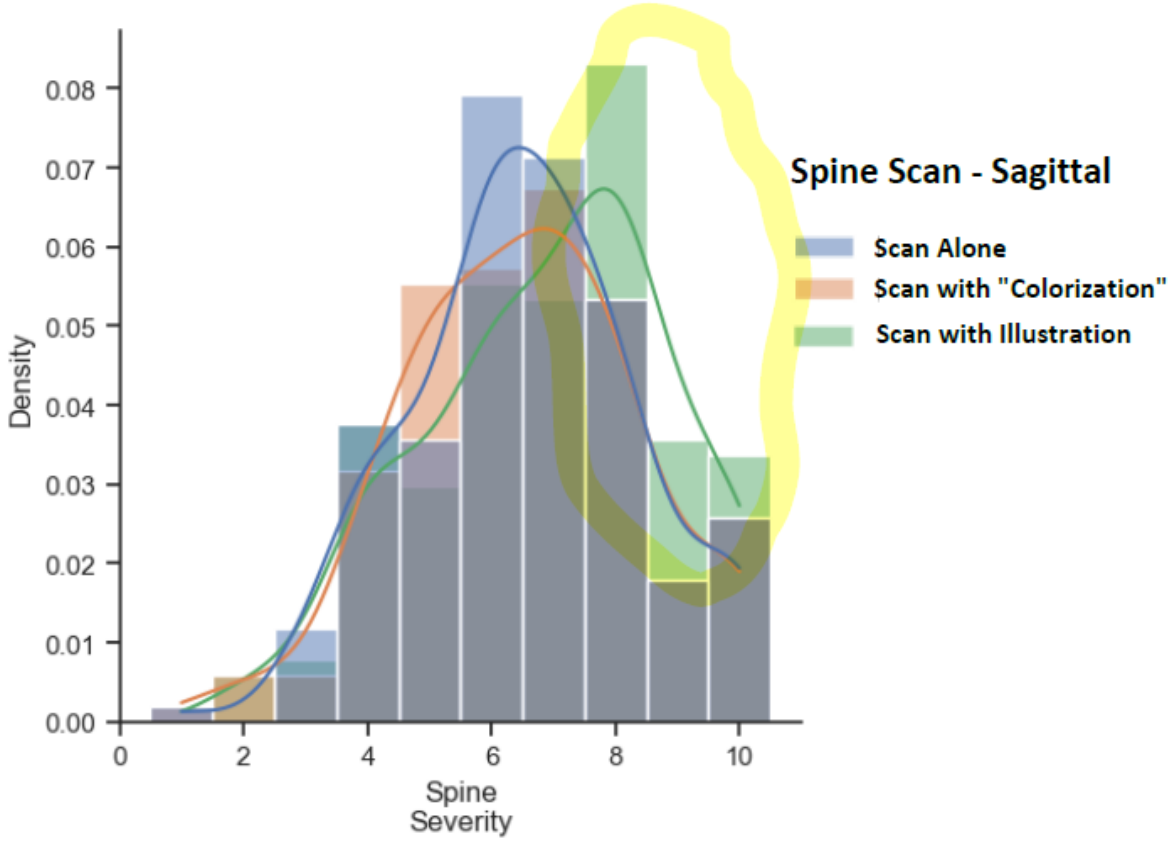
Spine Scan - Sagittal
Scan Alone
Scan with "Colorization"
Scan with Illustration
Density
0.00
0.01
0.02
0.03
0.04
0.05
0.06
0.07
0.08
0
2
4
6
8
10
Spine Severity

There are a few high-level takeaways from the study, organized here, loosely by topic:

Blood/No Blood

- Adding blood and more realistic anatomical images to the graphics did not increase the perception they were professional. But this is likely because almost all jurors perceived all images as professional.
- Adding blood and more realistic anatomical images to the graphics typically increased the perception the images were "precise" and that they were "expensive."
- Perhaps most surprisingly, adding blood and more realistic anatomical images to the graphics dramatically increased the perception the graphics were "clear and easy" to understand. Indeed, in some instances, almost twice as many jurors viewed the images as clear and easy to understand when the images included blood, etc.
- The probability that jurors would rate injury as very severe (8 or above on a 10-point scale) increased significantly when blood and realistic anatomical images were added to the graphics.
- Graphics with blood and more realistic anatomical images consistently increased the range of awards. Often, we saw jurors give hundreds of thousands of dollars more when they saw the images with blood, etc.
- The results are true for animations. For example, a simple clinical animation of a knee repair was compared to a more realistic and detailed animation that included flesh and blood. The flesh and blood presentation produced higher scores on every metric and significantly increased the likelihood of a finding the injury was severe.
- We also found that more blood is, in general, better. In at least one set of images, we compared a relatively bloody image of a calf to an even more bloody image. The bloodier image increased perceptions of severity of injury.